

Functional Outcome and Complications Following PHILOS Plate Fixation in Proximal Humeral Fractures

Shafqat Hussain, Muhammad Suhail Amin*, Mehmood Hussain**, Ali Arslan Munir***, Sundus Jabeen****, Muhammad Noman Iqbal

Department of Orthopedics, Combined Military Hospital/National University of Medical Sciences (NUMS) Rawalpindi Pakistan, *Department of Orthopaedic, Army Medical College/National University of Medical Sciences (NUMS) Rawalpindi Pakistan, **Department of Medicine, Pak Emirates Military Hospital/National University of Medical Sciences (NUMS) Rawalpindi Pakistan, ***Department of Anesthesia, CMH Institute of Medical Sciences Bahawalpur/National University of Medical Sciences (NUMS) Pakistan, ****Army Medical College/National University of Medical Sciences (NUMS) Rawalpindi Pakistan,

ABSTRACT

Objective: The purpose of this study is to assess the functional outcome following plate fixation with the Proximal Humeral Internal Locking System and to study complications associated with it.

Study design: Prospective longitudinal study.

Place and duration of study: Department of Orthopedic Surgery, Combined Military Hospital, Rawalpindi Pakistan, for 14 months from 01 Sep 2021 – 31 Oct 2022.

Methodology: A total of 75 patients participated in this study. Patients included in the study were aged 18 years or above with displaced proximal Humeral fractures. Patients were selected from in-patient department. They were explained the purpose of the study and those who consented to participate in the study were enrolled through a written consent form. Proximal Humeral Interlocking system was applied under general anesthesia. Follow up at 01 months, 03 months and 06 months was carried out for functional outcome & complications if any.

Results: A total of 75 patients were registered in this study. Average age of cohort was 42.05 ± 15.83 years with 46 males and 29 females. At 06 months the mean Constant score of the cohort was 58.96 ± 6.44 and mean ASES score was 60.15 ± 8.08 . Most common complication seen was superficial wound site infection with a frequency of 6(8%) that was resolved with dressing.

Conclusion: Functional outcome of Proximal Humeral Fractures managed with Interlocking system is very effective, though it declines with age.

Early mobilization of shoulder joint is achievable without compromising union of fracture segments.

Keywords: Interlocking system, locking plate, Proximal humeral fracture, PHILOS.

How to Cite This Article: Hussain S, Amin MS, Hussain M, Munir AA, Jabeen S, Iqbal MN. Functional Outcome and Complications Following PHILOS Plate Fixation in Proximal Humeral Fractures. Pak Armed Forces Med J 2024; 74(Suppl-2): S247-S251. DOI: <https://doi.org/10.51253/pafmj.v74iSUPPL-2.10439>

This is an Open Access article distributed under the terms of the Creative Commons Attribution License (<https://creativecommons.org/licenses/by-nc/4.0/>), which permits unrestricted use, distribution, and reproduction in any medium, provided the original work is properly cited.

INTRODUCTION

Trauma remains a significant cause of both morbidity and mortality on a global scale. Proximal Humeral Fractures, which account for approximately 5% of all fracture cases, often exhibit a high degree of displacement, with roughly 20% falling into this category. These fractures are typically classified using NEER'S Classification, which considers both the degree of displacement and the angle of anatomical segments.

When it comes to managing displaced fractures, several treatment options are available. However, as of now, there is no universally standardized approach. The lack of consensus stems from the fact that these options have been associated with suboptimal functional outcomes. To evaluate functional outcomes, the American Shoulder & Elbow Society (ASES) and

the Constant Murley Scoring System are commonly employed.

In order to enhance stability, novel plating techniques have emerged. However, the management of displaced proximal humeral fractures continues to be a subject of controversy, resulting in the proposal of various treatment methods over time. The specific role of surgery in this context remains ambiguous and lacks clear definition. Currently, there is a growing inclination towards minimizing soft tissue dissection and employing minimal hardware for achieving stability.¹

Up to 80% of proximal humeral fractures can be treated non-operatively, resulting in satisfactory results.² However, different techniques have been described for the fixation of comminuted and displaced proximal humeral fractures, including sutures, cerclage wires, K-wires, screws and plates, intramedullary devices, and shoulder arthroplasty.³ The complication rate can be as high as 50% or higher.⁴

Correspondence: Dr Shafqat Hussain, Department of Orthopaedic, Combined Military Hospital, Rawalpindi Pakistan

Received: 05 Jun 2023; revision received: 14 Nov 2023; accepted: 15 Nov 2023

Several complications have been reported, such as cut-out or back-out of the screws and plates, nonunion, avascular necrosis, nail migration, rotator cuff impairment, and impingement syndrome. Even shoulder arthroplasty in proximal humeral fractures may yield functionally poor results.

To reduce the occurrence of complications, specifically fixation failure and loss of stability, and to facilitate early postoperative mobilization, advancements have been made in the form of new plating techniques. One such technique is the Proximal Humeral Internal Locking System (PHILOS, Synthes, Solothurn, Switzerland). The development of this system aims to enhance stability and promote better outcomes by employing innovative approaches.⁵

Since there is a high correlation between the holding capacity of screws and regional bone morphology (e.g., cortical thickness and bone mineral density), osteoporotic bone is implicated in the occurrence of complications in proximal humeral fractures.⁶ The aim of the present study was to evaluate the clinical results of PHILOS plate fixation in proximal humeral fractures and to analyze potential implant-related complications.

METHODOLOGY

This study prospective, longitudinal study was conducted in Combined Military Hospital (CMH) Rawalpindi, for 14 months from September 2021 till Oct 2022. The ethical committee certificate was obtained from respective board (IERB Cert No:13-9-22). Written informed consent was taken from patients.

Inclusion Criteria: The inclusion criteria for this study encompassed patients who had a closed fracture of the proximal humerus and were 18 years of age or older, while also being deemed suitable for surgical intervention.

Exculsion Criteria: On the other hand, the following groups of individuals were excluded from participation: those with pathological fractures, open fractures, individuals with diabetes, and patients who expressed unwillingness to be part of the study.

The sample size calculation was conducted using the WHO sample size calculator. The study titled "Functional Outcome and Complications in Management of Proximal Humerus Fractures Operated with Proximal Humerus Locking Plate" by George *et al.* (2021) served as the parent study for determining the sample size. By considering the mean

Constant Murley score from the aforementioned study and applying a margin of error of 5%, an initial sample size of 10 individuals was estimated. However, in order to achieve better precision and mitigate the potential for failure to follow-up, efforts were made to increase the sample size to 80 patients. Sampling technique was non-probability, consecutive sampling.

In this study, patients with proximal humerus fractures were treated using the PHILOS system, and the evaluation focused on assessing the functional outcome and complications associated with this treatment approach. The American Shoulder and Elbow Score (ASES) and Constant Murley Score were utilized as measurement tools. To obtain a comprehensive understanding of the fractures, computed tomography (CT) scans were performed for all patients. These scans were instrumental in determining the extent of intra-articular involvement, and subsequently, the fractures were classified according to the Neer classification system. For the management of these fractures, all patients underwent open reduction internal fixation utilizing the PHILOS plate. This surgical technique was employed uniformly across the study population.

Patients underwent general anesthesia and were positioned in the beach chair position. The proximal humerus was accessed through a delto-pectoral approach, and the humeral head and tuberosity fragments were manipulated and temporarily stabilized using K-wires. The PHILOS plate was carefully positioned approximately 8-10 mm distal to the upper edge of the greater tuberosity. Placement of the plate was done with caution to avoid subacromial impingement, ensuring sufficient space between the plate and the long head of the biceps. A drill-sleeve system was employed for this procedure.

The plate fixation began by securing it distally using cortical screws. The rotator cuff tendons, along with any avulsed bony fragments, were then secured to the plate using tiger wire or vicryl sutures. Subsequently, the plate was firmly secured proximally with a minimum of four locking screws and distally with at least three screws. Intraoperatively, the mobility and quality of fixation were assessed. The wound was thoroughly washed, closed without the use of a drain, and all patients received standard antibiotic treatment.

Postoperatively passive mobilization was started immediately followed by active mobilization without the addition of weight, with full active mobilization

initiated in week six. Progressive strengthening exercises of the shoulder were commenced at twelve weeks. All patients were followed up with radiographs and clinical evaluation according to the Constant-Murley shoulder score and ASES score at 1, 3-and 6-months after surgery.

For data analysis, Microsoft Excel 365. Qualitative variables were represented as frequency and percentages while quantitative variables were reported as mean and standard deviation. For determining the association of mean constant score, chi-square test was applied keeping p -value of <0.05 as statistically significant.

RESULTS

From the total of 75 patients, mean age of patients was 42.05 ± 15.83 years wherein 46(61.3%) were males and 29(38.7%) were females. With regards to the ASA status, 30(40%) of patients were ASA I, i.e. had no other systemic disease while 45(60%) of patients were ASA II, having mild systemic disease, as shown in Table-I.

Table-I Patient demographics and Surgical factors (n=75)

Variables		Mean \pm SD/ Frequency (%)
Age (Years)		56.71 \pm 4.9
Weight (kg)		67.37 \pm 14.89
Gender	Male	34(46%)
	Female	41(54%)
ASA	I	30(40%)
	II	45(60%)

Data were denoted as Mean \pm SD except otherwise indicated.

A total of 75 patients were registered in this study. At 06 months the mean Constant score of the cohort was 58.96 ± 6.45 . The mean Constant score improved significantly between each follow-up interval ($p < 0.05$). The mean constant scores are tabulated as Table-II.

Table-II Mean Constant Scores at 01-, 03- and 06-months interval (n=75)

Follow up Period	Mean Constant Score
01 month	35.33 \pm 6.11
03 months	47.56 \pm 5.25
06 months	58.96 \pm 6.44

Similarly, mean ASES score over 1, 3 and 6 months demonstrated a gradual increase. At 1 month mean ASES score was 36.84 ± 6.47 , at 3-month interval it was 49.613 ± 7.22 and 6-month score was 60.15 ± 8.08 .

The rise in mean ASES score over 3 months was statistically significant ($p < 0.05$).

Wound site infection was the most common post op complication seen in this cohort with a frequency of 6(8%). Other notable complications seen were non-union, neuromuscular injury, vascular injury and avascular necrosis of humeral head. Absolute frequencies of these complications are described in Figure-1.

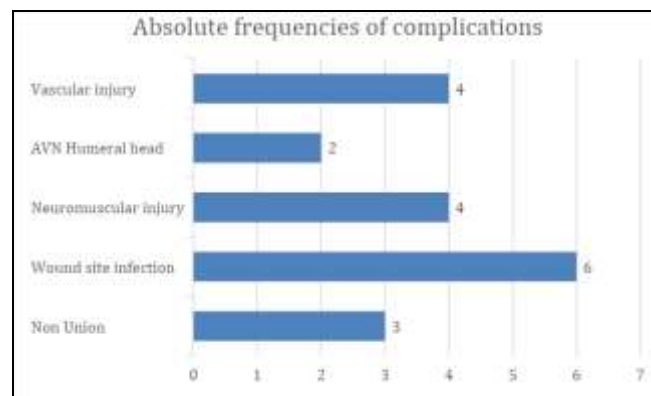


Figure-1: Absolute Frequencies of Complications

DISCUSSION

A comprehensive literature search was performed on the PubMed, Web of Science, Embase, and Cochrane databases up to 7 October 2021.⁷ Studies describing medium and long-term complications in proximal humerus fracture using the PHILOS plate were included. A systematic review and meta-analysis were performed on complications and causes of reinterventions. Proximal humerus synthesis with a PHILOS plate has advantages and complications and reintervention rates.⁸ The most frequent complication was screw cut-out, followed by humeral head AVN and subacromial impingement. These results need to be further investigated to better understand both the type of patient and fracture that is more at risk of complications and reintervention and to compare pros and cons of the PHILOS plate with respect to the other solutions to manage proximal humerus fractures.⁹

The functional outcome following PHILOS plate fixation in proximal humerus fracture is influenced by several factors, such as fracture type, reduction quality, surgical technique, rehabilitation protocol and patient characteristics. The most commonly used outcome measures are the Constant-Murley score (CMS), the Disabilities of the Arm, Shoulder and Hand score (DASH) 9 and the visual analog scale (VAS) for pain. According to a meta-analysis by Zhang *et al.* the

mean CMS at 12 months after PHILOS plate fixation was 72.4 ± 10.6 , which was comparable to other fixation methods such as intramedullary nails, hemiarthroplasty and reverse shoulder arthroplasty. The study conducted by Vidovic *et al.* in Croatia concluded that PHILOS plate fixation results were comparable to other types of fixations with reduced complications rate.¹⁰ Overall, PHILOS was the most tested plate and locking plates demonstrated better mechanical performance than non-locking ones was the conclusion drawn by Jabran *et al.* as well.¹¹

The complications following PHILOS after proximal humerus fracture can be classified into intraoperative and postoperative complications. The intraoperative complications include axillary nerve injury, vascular injury, rotator cuff injury and screw perforating articular surface. The postoperative complications include infection, nonunion, malunion, avascular necrosis (AVN), impingement syndrome and hardware irritation. The reported incidence of complications varies widely among different studies, ranging from 0% to 68%. The most common complications are screw perforation (8% to 32%), AVN (5% to 34%) and nonunion (3% to 25%).¹² The study conducted by Oldrini *et al.* showed multiple complication associated with the procedures and reflects different time frames for developments.¹³ Similarly, in a study by Li M *et al.* most common complication was postoperative infection which can be avoided.¹⁴

A study conducted in Baltimore showed lower incidence of internal fixation failure at 30 days using PHILOS plating technique.¹⁵ Similarly, another study conducted by Zyto K showed no functional differences among groups with optimum function achieved at 01-year duration.¹⁶ Another long term follow-up study showed that if not properly treated, pain can have significant impact in regaining shoulder strength and range of motions.^{17,18}

This study has numerous strong points. It is well designed, single-centered, observational study with a good sample size. To our knowledge, this is the earliest study in military set up in Pakistan to see functional outcome and complication. This study has helped in consolidating the knowledge about this safe and well-practiced procedure hence made it easier for limited resource countries like ours to go for cheaper option with equal efficacy.

ACKNOWLEDGEMENTS

The authors are highly obliged to Advisor in Orthopedics, surgery colleagues, anesthesiologists, contemporaries, OR Staff and patients for their kind & effective assistance in conducting the study.

LIMITATIONS OF STUDY

The study was performed at only one centre and it excluded diabetic patients and open fractures

CONCLUSION

PHILOS plate is an effective system in providing fracture stabilization in proximal humeral fractures for union to occur. The usage of the PHILOS plate also allows early mobilization and a good functional outcome for patients with very few complications.

Conflict of Interest: None.

Funding Source: None.

Authors' Contribution

The following authors have made substantial contributions to the manuscript as under:

SH & MSA: Study design, drafting the manuscript, data interpretation, critical review, approval of the final version to be published.

MH & AAM: Data acquisition, data analysis, approval of the final version to be published.

SJ & MNI: Critical review, concept, drafting the manuscript, approval of the final version to be published.

Authors agree to be accountable for all aspects of the work in ensuring that questions related to the accuracy or integrity of any part of the work are appropriately investigated and resolved.

REFERENCES

1. Seebeck J, Goldhahn J, Städele H, Messmer P, Morlock MM, Schneider E, et al. Effect of cortical thickness and cancellous bone density on the holding strength of internal fixator screws. *J Orthop Res* 2004; 22: 1237-42.
<https://doi.org/10.1016/j.jorthres.2004.04.001>
2. Saber AY, Said UN, Abdelmonem AH. Surgical Fixation of Three- and Four-Part Proximal Humeral Fractures Using the Proximal Humeral Interlocking System Plate. *Cureus* 2022; 14(5): e25348. Published 2022 May 26.
<https://doi.org/10.7759/cureus.25348>
3. Canale ST, Azar FM, Beaty JH. Open reduction and internal fixation of proximal humeral fractures with use of the locking proximal humerus plate. Results of a prospective, multicenter, observational study. *Campbell's Operative Orthopaedics*. Elsevier; 2017.
4. Südkamp N, Bayer J, Hepp P. Constant-Murley Score: systematic review and standardized evaluation in different shoulder pathologies. *J Bone Joint Surg Am* 2009; 91: 1320-1328.
5. Vrotsou K, Ávila M, Machón M, Mateo-Abad M, Pardo Y, Garin O et al. Constant-Murley Score: systematic review and standardized evaluation in different shoulder pathologies. *Qual Life Res* 2018; 27(9): 2217-2226.
<https://doi.org/10.1007/s11136-018-1875-7>

6. Jabran A, Peach C, Ren L. Biomechanical analysis of plate systems for proximal humerus fractures: a systematic literature review. *Biomed Eng Online* 2018; 17(1): 47. Published 2018 Apr 27. <https://doi.org/10.1186/s12938-018-0479-3>
7. Windolf M, Knierzinger D, Nijs S. In Vitro Testing and Clinical Handling of a Novel Implant Positioning Technology for Proximal Humeral Plating. *Medicina (Kaunas)* 2023; 59(3): 450. <https://doi.org/10.3390/medicina59030450>
8. Laux CJ, Grubhofer F, Werner CML, Simmen HP, Osterhoff G. Current concepts in locking plate fixation of proximal humerus fractures. *J Orthop Surg Res* 2017; 12(1): 137. <https://doi.org/10.1186/s13018-017-0639-3>
9. Plath JE, Kerschbaum C, Seebauer T. Locking nail versus locking plate for proximal humeral fracture fixation in an elderly population: a prospective randomised controlled trial. *BMC Musculoskelet Disord* 2019; 20(1): 20. <https://doi.org/10.1186/s12891-019-2399-1>
10. Vidović D, Benčić I, Cuti T. Treatment of humeral shaft fractures: antegrade interlocking intramedullary nailing with additional interlocking neutralization screws through fracture site. *Acta Clin Croat* 2019; 58(4): 632-638. <https://doi.org/10.20471/acc.2019.58.04.10>
11. Jabran A, Peach C, Ren L. Biomechanical analysis of plate systems for proximal humerus fractures: a systematic literature review. *Biomed Eng Online* 2018; 17(1): 47. <https://doi.org/10.1186/s12938-018-0479-3>
12. Shi X, Liu H, Xing R. Effect of intramedullary nail and locking plate in the treatment of proximal humerus fracture: an update systematic review and meta-analysis. *J Orthop Surg Res* 2019; 14(1): 285. <https://doi.org/10.1186/s13018-019-1345-0>
13. Oldrini LM, Feltri P, Albanese J, Marbach F, Filardo G, Candrian C, et al. PHILOS Synthesis for Proximal Humerus Fractures Has High Complications and Reintervention Rates: A Systematic Review and Meta-Analysis. *Life (Basel)* 2022; 12(2): 311. <https://doi.org/10.3390/life12020311>
14. Li M, Wang Y, Zhang Y, Yang M, Zhang P, Jiang B, et al. Intramedullary nail versus locking plate for treatment of proximal humeral fractures: A meta-analysis based on 1384 individuals. *J Int Med Res* 2018; 46(11): 4363-4376. <https://doi.org/10.1177/0300060518781666>
15. Chen X, Yu ZX, Wang HY. Proximal humeral internal locking plate combined with a custom neutral-position shoulder and elbow sling for proximal humerus fractures: A randomized study. *Medicine (Baltimore)* 2019; 98(17): e15271. <https://doi.org/10.1097/MD.00000000000015271>
16. Zyto K, Ahrengart L, Sperber A, Törnkvist H. Treatment of displaced proximal humeral fractures in elderly patients. *J Bone Joint Surg Br* 1997; 79(3): 412-7. <https://doi.org/10.1302/0301-620x.79b3.7419>
17. Movin T, Sjöden GO, Ahrengart L. Poor function after shoulder replacement in fracture patients. A retrospective evaluation of 29 patients followed for 2-12 years. *Acta Orthop Scand* 1998; 69(4): 392-6. <https://doi.org/10.3109/17453679808999053>
18. Frigg R. Development of the Locking Compression Plate. *Injury* 2003; 34 Suppl 2: B6-10. <https://doi.org/10.1016/j.injury.2003.09.020>
19. Saber AY, Said UN, Abdelmonem AH, Elsayed H, Taha M, Hussein W, et al. Surgical Fixation of Three- and Four-Part Proximal Humeral Fractures Using the Proximal Humeral Interlocking System Plate. *Cureus* 2022; 14(5): e25348. <https://doi.org/10.7759/cureus.25348>