

Comparative Outcomes of Chronic Subdural Hematoma Management: Surgery Combined with Middle Meningeal Artery Embolization vs. Surgery Alone

Muhammad Usman, Maqsood Akram, Waqas Ahmed, Muhammad Junaid, Zahid Hussain, Muhammad Talha Makshoof

Department of Neurosurgery, Combined Military Hospital, Rawalpindi/National University of Medical Sciences (NUMS) Pakistan

ABSTRACT

Objective: To compare outcomes of middle meningeal artery embolization combined with surgical evacuation versus surgical treatment alone in patients presenting with chronic subdural hematoma in terms of frequency of recurrence and mortality.

Study Design: Quasi experimental study.

Place and Duration of Study: Neurosurgery Department of Combined Military Hospital Rawalpindi, Pakistan and Armed Forces Institute of Radiology and Imaging Rawalpindi, Pakistan from Jun 2022 to Jun 2024

Methodology: Patients with chronic subdural hematoma who underwent treatment in our department were recruited in the study. Patients were divided into two groups: those who received surgical drainage alone (Group-A, 49 patients) and those treated with both surgical drainage and middle meningeal artery embolization (Group-B, 55 patients). Outcome in both the study groups was assessed at the end of six months of procedure in terms of recurrence of hematoma or mortality.

Results: A total of 104 patients were recruited in this study. Out of these, 78 patients were male (75%) while 26 patients were female (25%). Mean age of patients was 54.7±12.1 years. Fifty-five patients (52.9%) underwent middle meningeal artery embolization after surgery while 49 patients (47.1%) underwent surgery alone. Recurrence rate ($p=0.006$) and mortality ($p=0.04$) were significantly high in patients who underwent surgery alone ($p<0.05$).

Conclusion: The addition of middle meningeal artery embolization to conventional surgical evacuation for chronic subdural hematoma significantly reduced the recurrence rate and mortality in our study participants as compared to surgical management alone.

Keywords: Chronic Subdural Hematoma, Embolization Middle Meningeal Artery, Mortality, Recurrence.

How to Cite This Article: Usman M, Akram M, Ahmed W, Junaid M, Hussain Z, Makshoof MT. Comparative Outcomes of Chronic Subdural Hematoma Management: Surgery Combined with Middle Meningeal Artery Embolization vs. Surgery Alone. Pak Armed Forces Med J 2026; 76(Suppl-3): S565-S568. DOI: <https://doi.org/10.51253/pafmj.v76iSUPPL-3.13602>

This is an Open Access article distributed under the terms of the Creative Commons Attribution License (<https://creativecommons.org/licenses/by-nc/4.0/>), which permits unrestricted use, distribution, and reproduction in any medium, provided the original work is properly cited.

INTRODUCTION

Neurosurgery is a constantly evolving field of medicine having great reduction in procedures mortality and morbidity in last two decades across the globe.¹ Chronic subdural hematoma (CSDH) has been one of the commonly encountered condition by neurosurgeons.² Epidemiological statistics in Pakistan are not similar to other parts of the world.³ Common causes of CSDH include old age, alcohol use, use of anti-inflammatory medications, coagulopathies etc.⁴

A number of management techniques have been used but surgery remains treatment of choice for CSDH.⁵ In recent past embolizing the meningeal artery along with surgical removal has been emerging as a preferred option for CSDH.⁶ There is a constant comparison in all medical fields between surgical and minimally invasive methods of treatment. Same has been case with management of CSDH. A study from

2022 highlighted the efficacy and safety of middle meningeal artery (MMA) embolization procedure for management of CSDH.⁷

Sila et al. compared surgical management and MMA embolization for treatment of CSDH and reported that size of hematoma, mid-line shift and presence of acute hematoma should be taken into account before choosing the treatment modality.⁸ A similar study concluded that combination of MMA embolization followed by surgical evacuation of hematoma may be more beneficial as compared to both the methods when used alone. Embolization of MMA after the surgery also reduced the chances of recurrence in their study.⁹

Minimally invasive procedures have been gaining popularity in neurosurgery but evolution is slow in our part of the world. A recent local study compared one burr-hole versus two burr-holes technique for evacuation of CSDH.¹⁰ Limited local data has been generated on the subject. We therefore planned this study with the rationale to compare MMA embolization combined with surgical

Correspondence: Dr Muhammad Usman, Department of Neurosurgery, Combined Military Hospital, Rawalpindi Pakistan
Received: 26 Jun 2025; revision received: 04 Aug 2025; accepted: 06 Aug 2025

Chronic Subdural Hematoma Management

evacuation against surgical treatment alone in reducing the recurrence rates of CSDH and mortality.

METHODOLOGY

This quasi-experimental study was conducted at Neurosurgery Department Combined Military hospital (CMH) Rawalpindi, Pakistan and Armed Forces Institute of Radiology and Imaging (AFIRI) Rawalpindi, Pakistan from June 2022 to June 2024. Research evaluation and the ethical committee of CMH Rawalpindi approved the study via (letter no 757, dated 20 Dec 2024).

Inclusion Criteria: All patients of either gender between the age of 18 to 70 years who were confirmed to have CSDH on CT scan brain by consultant radiologist and neurosurgeon were included.

Exclusion Criteria: Patients with any uncontrolled hypertension, ischemic heart disease, coagulation disorders or autoimmune disorders, those with concomitant other pathologies on CT scan brain, those with redo-surgeries or those with sudden unexplained death during or immediately after the surgery, and patients who lost to follow up with the team were excluded.

Sample size was calculated by using the WHO sample size calculator by taking study by Enriquez-Marulanda et al. as the parent study.¹¹ The population proportion 1 as 0.0% and population proportion 2 as 12% (mortality). The minimum sample size determined for each Group-was 45 patients. Non-probability consecutive sampling method was used to recruit patients, and written informed consent was taken. All enrolled patients were managed at our hospital. Patients were diagnosed with CSDH by a consultant neurosurgeon on the basis of relevant clinical and neuro imaging findings.^{12,13} They were randomly divided into two groups via lottery method at the time of management. Patients in Group-A underwent surgery alone while those in Group-B underwent MMA embolization after the surgery (Figure-1). Surgery was performed by consultant neurosurgeon via burr hole technique.¹⁴ MMA embolization was done by Interventional radiologist especially trained in this procedure.¹⁵

Patients of both groups were kept in surgical ICU for twenty-four hours after the surgery and later shifted to HDU of neurosurgical ward. Follow up of patients was ensured by taking their contact numbers. They were followed up for six months on a monthly basis and repeated brain scans were also performed by

the treating team if required. Recurrence was defined as re-emergence of CSDH on follow up scans within 6 months. The final data was gathered on the 6 monthly follow up visit.

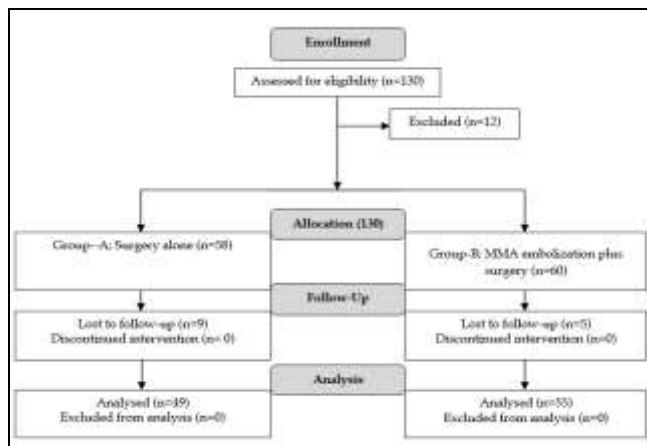


Figure-1: Patient's Flow Diagram (n=104)

Statistical analysis was carried out with Statistical Package for Social Sciences (SPSS) version 23.0. Mean±SD was calculated for age of patients. Frequency along with percentage was calculated for gender and other demographic and outcome variables. Pearson chi-square or Fischer exact tests were used to assess association between two study groups by keeping the *p*-value less than or equal to 0.05 as significant.

RESULTS

A total of 104 patients who underwent management for CSDH were recruited in this study. Out of these, 78(75%) were male patients while 26(25%) were female. Mean age of patients who were managed for CSDH at our department in given time period was 54.9±12.1 years. Table-I summarizes characteristics of patients. Out of total patients 55 (52.9%) underwent MMA embolization after surgery while 49 (47.1%) underwent surgery alone.

Table-I: Profile of Study Participants (n=104)

Variable	Variable Groups	Group-A (n=49) n(%)	Group-B (n=55) n(%)	<i>p</i> -value
Age (years)	Mean±SD	54.8±13.3	54.6±11.1	-
Gender	Male	34(69.4%)	44(80.0%)	0.212
	Female	15(30.6%)	11(20.0%)	
Main Symptom	Headache	23(46.9%)	24(43.6%)	0.797
	Nausea	7(14.3%)	12(21.8%)	
	Vomiting	10(20.4%)	11(20.0%)	
	Weakness	8(16.3%)	6(10.9%)	
	Seizures	1(2.0%)	2(3.6%)	

Chronic Subdural Hematoma Management

Table-II summarizes the results of statistical analysis. It was revealed that recurrence rate and mortality after 6 months of the procedures in both the groups were seen more in patients who underwent surgery only. Both the complications were significantly high in patients who underwent surgery only ($p < 0.05$) as compared to those who underwent MMA embolization after the surgery. Both the recurrence and mortality was found to be higher among the male patients as compared to female patients.

Table-II: Association of Various Outcome Parameters Across Groups (n=104)

Outcomes	Result	Group-A (n=49) n(%)	Group-B (n=55) n(%)	p-value
Recurrence	Yes	12(24.5%)	3(5.5%)	0.006
	No	37(75.5%)	52(94.5%)	
Mortality	Yes	9(18.4%)	3(5.5%)	0.040
	No	40(81.6%)	52(94.5%)	

DISCUSSION

The integration of MMA embolization with surgical evacuation marks a pivotal development in the management of CSDH. This combined strategy aims to reduce recurrence rates, optimize recovery, and potentially lower healthcare utilization and costs. In a developing country like Pakistan, recurrence of a potentially lethal medical condition is devastating news for the patient as well as family. Minimizing the chances of complications and recurrence after a procedure is a real success for the treating team. Multidisciplinary approach involving both neurosurgery and interventional radiology teams in order to make the management plan more effective is need of the hour for patients suffering from CSDH.¹²

A study by Salih *et al.*, published in 2022 reported that there was a significant reduction in recurrence rates in patients who had adjunct MMA embolization with conventional drainage of CSDH. The frequency of recurrence in MMA embolization coupled with evacuation was 5.4% versus 19.7% in patients undergoing conventional burrhole evacuation alone, the difference being statistically significant ($p = 0.037$).⁹

Pre-operative prophylactic MMA embolization, when combined with surgical drainage, significantly reduced the recurrence rates of CSDH in 44 cases studied by Schwarz *et al.*¹⁶ Embolization may be useful by reducing the vascular contributions to hematoma re-accumulation. Similar results were seen in our study, as patients who underwent MMA embolization

had better outcome as compared to those who only underwent surgery. The variation in our study and method was that we opted for MMA embolization after the surgery.

A study from Germany published in 2022 compared outcomes in patients of CSDH managed with surgery alone and surgery followed by MMA embolization. It was revealed that recurrence rate was significantly reduced in patients who underwent MMA embolization as compared to those who underwent surgery alone.¹⁷ We studied two outcome parameters i.e. recurrence and mortality within six months of treatment. Both parameters were better in cohorts who were managed with combined approach with the difference being statistically significant ($p < 0.05$).

Sattari *et al.* in 2023 published a systematic review and meta-analysis regarding comparison of patients who underwent only surgical management versus those who underwent combination of surgery and MMA embolization. They concluded that MMA embolization improved mortality and morbidity in these patients.¹⁸ Our results reflected that the addition of MMA embolization to conventional surgical evacuation for CSDH significantly reduced the recurrence rate and mortality in our patients. as compared to surgical management alone. These results support the integration of MMA embolization into standard treatment protocols for CSDH.

Chen *et al.*, published a multi-centre study in 2023 and compared the two methods for management of CSDH. They came up with the findings that even standalone, MMA embolization had comparable results with that of combining embolization with surgery.¹⁹ We did not compare standalone MMA embolization procedure with combination treatment or surgery alone but comparing combination treatment with surgery standalone revealed that combination of surgery and MMA embolization had better outcome in terms of less recurrence and mortality.

LIMITATIONS OF STUDY

Loss to follow-up rate was high in our study which may prone the results towards bias. Parameters other than hematoma recurrence and mortality should also be carefully studied in future studies with a better prospective design in order to formulate local guidelines in this regard.

CONCLUSION

The addition of MMA embolization to conventional surgical evacuation for CSDH significantly reduced the

Chronic Subdural Hematoma Management

recurrence rate and mortality in our study participants as compared to surgical management alone. These results support the integration of MMA embolization into standard treatment protocols for CSDH.

Conflict of Interest: None.

Funding Source: None.

Authors' Contribution

Following authors have made substantial contributions to the manuscript as under:

MU & MA: Data acquisition, data analysis, critical review, approval of the final version to be published.

WA & MJ: Study design, data interpretation, drafting the manuscript, critical review, approval of the final version to be published.

ZH & MTM: Conception, data acquisition, drafting the manuscript, approval of the final version to be published.

Authors agree to be accountable for all aspects of the work in ensuring that questions related to the accuracy or integrity of any part of the work are appropriately investigated and resolved.

REFERENCES

1. Buwaidar A, Sæmundsson B, Nemer E, Anderberg J, Strom I, Wong SS, et al. Outcomes after standardized burr-hole surgery for chronic subdural hematomas: a population-based consecutive cohort study of 2655 patients. *Neurosurg* 2025; 97(2): 298-309. <https://doi.org/10.1227/neu.0000000000003320>
2. Sadeghian H, Chida K, Motiei-Langroudi R. Editorial: Chronic subdural hematoma: Overview of recent therapeutic advancements. *Front Neurol* 2023; 14(3): 1155680. <https://doi.org/10.3389/fneur.2023.1155680>
3. Sarwar MA, Ali K, Hussain K, Shahid S, UIAbidin Z, Abid M, et al. Management and outcome of chronic subdural hematoma: a prospective study of Shaikh Zayed Hospital, Lahore. *Pak J Neurol Surg* 2018; 22(1): 24-32.
4. Uno M. Chronic subdural hematoma-evolution of etiology and surgical treatment. *Neurol Med Chir* 2023; 63(1): 1-8. <https://doi.org/10.2176/jns-nmc.2022-0207>
5. Zolnourian A, Manivannan S, Edwards B, Chua A, Arora M, Akhigbe T, et al. Factors affecting outcomes following burr hole drainage of chronic subdural hematoma: a single-center retrospective study. *J Neurosurg* 2025; 142(6): 1606-1615. <https://doi.org/10.3171/2024.9.JNS24370>
6. Papageorgiou NM, Palaiodimou L, Melanis K, Theodorou A, Stefanou MI, Tsalouchidou PE, et al. Embolization of middle meningeal artery in patients with chronic subdural hematoma: a systematic review and meta-analysis of randomized-controlled clinical trials. *J Clin Med* 2025; 14(9): 2862. <https://doi.org/10.3390/jcm14092862>
7. Di Cristofori A, Remida P, Patassini M, Piergallini L, Buonanno R, Bruno R, et al. Middle meningeal artery embolization for chronic subdural hematomas. A systematic review of the literature focused on indications, technical aspects, and future possible perspectives. *Surg Neurol Int* 2022; 13(3): 94. https://doi.org/10.25259/SNI_911_2021
8. Sila D, Casnati FL, Vojtková M, Kirsch P, Rath S, Charvát F. Middle meningeal artery embolization versus surgery in patients with chronic subdural hematoma-no more fence sitting? *Neurol Int* 2023; 15(4): 1480-1488. <https://doi.org/10.3390/neurolint15040096>
9. Salih M, Shutran M, Young M, Vega RA, Stippler M, Papavassiliou E, et al. Reduced recurrence of chronic subdural hematomas treated with open surgery followed by middle meningeal artery embolization compared to open surgery alone: a propensity score-matched analysis. *J Neurosurg* 2022; 139(1): 124-130. <https://doi.org/10.3171/2022.11.JNS222024>
10. Shamim B, Ashraf AT, Mushtaq MJ, Bhangash KA, Khan AA, Ejaz M. Comparison of one versus two burr hole procedures in evacuation of chronic subdural hematoma. *Pak Armed Forces Med J* 2024; 74(1): 121-124. <https://doi.org/10.51253/pafmj.v74i1.4002>
11. Enriquez-Marulanda A, Gomez-Paz S, Salem MM, Mallick A, Motiei-Langroudi R, Arle JE, et al. Middle meningeal artery embolization versus conventional treatment of chronic subdural hematomas. *Neurosurgery* 2021; 89(3): 486-495. <https://doi.org/10.1093/neuros/nyab192>
12. Ishida T, Inoue T, Inoue T, Saito A, Suzuki S, Uenohara H, et al. Functional outcome in patients with chronic subdural hematoma: postoperative delirium and operative procedure. *Neurol Med Chir* 2022; 62(4): 171-176. <https://doi.org/10.2176/jns-nmc.2020-0319>
13. Hamou HA, Clusmann H, Schulz JB, Wiesmann M, Altiok E, Höllig A et al. Chronic subdural hematoma. *Dtsch Arztebl Int* 2022; 119(12): 208-213. <https://doi.org/10.3238/arztebl.m2022.0144>
14. Shim YW, Lee WH, Lee KS, Kim ST, Paeng SH, Pyo SY et al. Burr hole drainage versus small craniotomy of chronic subdural hematomas. *Korean J Neurotrauma* 2019; 15(2): 110-116. <https://doi.org/10.13004/kjnt.2019.15.e25>
15. Dinc R. Featured minimally invasive therapeutic approach for chronic subdural hematoma: embolization of middle meningeal artery - A narrative review. *Brain Circ* 2024; 10(1): 28-34. https://doi.org/10.4103/bc.bc_65_23
16. Schwarz J, Carnevale JA, Goldberg JL, Ramos AD, Link TW, Knopman J et al. Perioperative prophylactic middle meningeal artery embolization for chronic subdural hematoma: a series of 44 cases. *J Neurosurg* 2021; 135(6): 1627-1635. <https://doi.org/10.3171/2020.10.JNS202856>
17. Onyinzor C, Berlis A, Abel M, Kudernatsch M, Maurer CJ. Efficacy and mid-term outcome of middle meningeal artery embolization with or without burr hole evacuation for chronic subdural hematoma compared with burr hole evacuation alone. *J Neurointerv Surg* 2022; 14(3): 297-300. <https://doi.org/10.1136/neurintsurg-2021-017450>
18. Sattari SA, Yang W, Shahbandi A, Feghali J, Lee RP, Xu R, et al. Middle meningeal artery embolization versus conventional management for patients with chronic subdural hematoma: a systematic review and meta-analysis. *Neurosurgery* 2023; 92(6): 1142-1154. <https://doi.org/10.1227/neu.0000000000002365>
19. Chen H, Salem MM, Colasurdo M, Sioutas GS, Khalife J, Kuybu O, et al. Standalone middle meningeal artery embolization versus middle meningeal artery embolization with concurrent surgical evacuation for chronic subdural hematomas: a multicenter propensity score matched analysis of clinical and radiographic outcomes. *J Neurointerv Surg* 2024; 16(12): 1313-1319. <https://doi.org/10.1136/jnis-2023-020907>