

Comparison of Fiberoptic Bronchoscopy versus Landmark Technique for the quick insertion of Percutaneous Dilatation Tracheostomy Tube

Sanum Kashif, Ahmed Burki, Fatima Tassadaq Syed

Department of Critical Care Medicine, Combined Military Hospital/National University of Medical Sciences (NUMS), Rawalpindi Pakistan

ABSTRACT

Objective: To Compare Fiberoptic Bronchoscopy (FOB) versus Landmark technique for the quick insertion of Percutaneous Dilatation Tracheostomy Tube (PCDT).

Study Design: Quasi-experimental study.

Place and Duration of Study: Surgical ICU, Combined Military Hospital, Rawalpindi Pakistan, from Aug 2024 to May 2025.

Methodology: Patients were randomly divided into two groups via lottery method. In Group-A, Fiberoptic Bronchoscopy used for PCDT and in Group-B, Landmark technique was used for the insertion of PCDT tube. Correct placement of the endotracheal tube was ascertained by the chest x-ray in both the groups. The primary outcome was the procedural time of successful airway establishment and Secondary outcomes included complications (bleeding, hypoxia and esophageal injury).

Results: A total of 78 patients were included in the study. Procedural time was significantly longer in Fiberoptic Bronchoscopic group as compare to Landmark technique group (vs. 18.4±8.1 versus 12.9±4.7 min, $p<0.01$). Complications including, Bleeding (>50 mL) 15% in Group-A versus 9% in Group-B, Hypoxia was observed in 13% in Group-A versus 6% of cases in Group-B, whereas esophageal injury was not found in any of the group.

Conclusion: Percutaneous dilatation tracheostomy (PCDT) insertion with a landmark technique demonstrated superior performance in terms of procedural time as well as complications as compared to the fiberoptic bronchoscope technique.

Keywords: Fiberoptic Bronchoscopy, Insertion, Landmark Technique, Percutaneous Dilatation Tracheostomy.

How to Cite This Article: Kashif S, Burki A, Syed FT. Comparison of Fiberoptic Bronchoscopy versus Landmark Technique for the quick insertion of Percutaneous Dilatation Tracheostomy Tube. *Pak Armed Forces Med J* 2026; 76(Suppl-3): S629-S633.

DOI: <https://doi.org/10.51253/pafmj.v76iSUPPL-3.13857>

This is an Open Access article distributed under the terms of the Creative Commons Attribution License (<https://creativecommons.org/licenses/by-nc/4.0/>), which permits unrestricted use, distribution, and reproduction in any medium, provided the original work is properly cited.

INTRODUCTION

Tracheostomy is a lifesaving and frequently performed procedure in ICU for patients who require prolonged ventilatory support. It facilitates airway management, weaning, tracheobronchial hygiene, and patient comfort compared with extended endotracheal intubation.¹ Over recent years, percutaneous dilatational tracheostomy (PDT) has largely replaced the traditional surgical approach because of its simplicity, shorter procedure time, bedside feasibility, and lower infection risk.² Several procedural variations exist—landmark-guided, fiberoptic bronchoscope (FOB)-guided, and ultrasound-guided (USG)—each with unique advantages and limitations. According to Brass P and Klotz R, the use of FOB guidance enhances visualization of tracheal anatomy and may reduce the risk of posterior wall injury or false passage formation³ but it requires specialized equipment and expertise, limiting its application in many ICUs.⁴

Meta-analyses and comparative trials have

produced mixed findings. Some studies have reported that FOB-guided PDT reduces overall complication rates and improves first-attempt success compared with the landmark technique,⁵ whereas others found no significant difference in major complications but observed longer procedure times and transient hypoxia due to partial airway obstruction by the bronchoscope.⁶

Recent research has also focused on USG-guided PDT, which provides real-time visualization of neck structures and helps avoid vascular injury. Evidence suggests that ultrasound increases accuracy and safety but prolongs procedure time slightly.^{7,8} Despite abundant global data, evidence comparing landmark and FOB-guided PCDT in local ICU populations, especially within resource-limited settings, remains scarce. Therefore, this study was designed to compare fiberoptic bronchoscopy-guided and landmark-guided PCDT with respect to procedural efficiency and complication rates among critically ill patients.

METHODOLOGY

This quasi-experimental study was conducted at the Surgical ICU of Combined Military Hospital, Rawalpindi Pakistan, from August 2024 to May 2025.

Correspondence: Dr Sanum Kashif, Department of Critical Care Medicine, Combined Military Hospital, Rawalpindi Pakistan

Received: 17 Sep 2025; revision received: 31 Oct 2025; accepted: 03 Nov 2025

The study protocol was approved by the institutional review board vide ERC certificate number 901/2025 dated 14 July, 2025. By using WHO sample size calculator, a total sample size of 78 patients was calculated with complications rate of 7% incidence in the semi-surgical PCDT group as compared to 1% with Conventional PCDT group), level of significance 5% with 90% test power.

Inclusion Criteria: Adults patients of either gender requiring tracheostomy for prolonged ventilation (>7 days), who were hemodynamically stable (MAP >65 mmHg, no active bleeding) were included.

Exclusion Criteria: Patients with cervical spine injury, coagulopathy (INR >1.5, platelets <50,000/mm³) and previous tracheostomy or neck surgery were excluded.

Informed consent from the guardians of the participants, who were admitted and intubated in the surgical intensive care unit of CMH Rawalpindi, fulfilling the inclusion criteria were included. All participants were monitored closely during the study period. Adverse events were reported and managed appropriately.

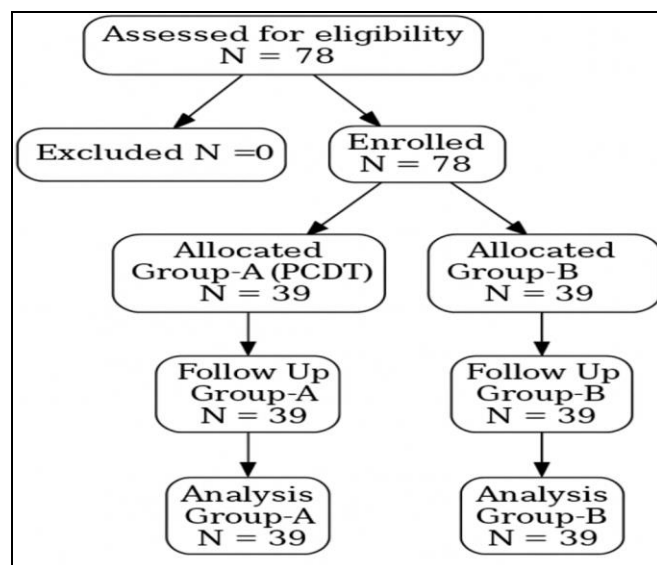


Figure: Patient Flow Diagram (n=78)

Patients were divided randomly into two groups via lottery method, Fiberoptic Bronchoscope Group (Group-A): Patients in which Fiberoptic Bronchoscope was used for PCDT and Landmark Group (Group-B): Patients in which Landmark technique is used for PCDT, (Figure). In both groups, patients were positioned supine with neck extension. A local anesthetic, injection Lignocaine (2%), 5ml, was infiltrated at the skin over cricothyroid membrane. In

Group-A, Bronchoscope was inserted through ETT to visualize trachea, needle puncture done, between 1st-2nd or 2nd-3rd tracheal rings under direct vision, followed by guidewire insertion, serial dilation, and tracheostomy tube placement, which later confirmed via bronchoscopy, at the end of the procedure. In Group-B, the cricothyroid membrane was identified through palpation, followed by palpation of tracheal ring. After local anesthetic infiltration, needle was inserted at between 1st-2nd or 2nd-3rd tracheal rings, followed by guidewire placement, dilation and then tracheal tube placement. Primary outcome was to compare the procedural time of successful airway establishment and Secondary outcome was to evaluate the first-attempt success rate and Complications (Bleeding, Number of hypoxic events, esophageal injury).

The data analysis was done using Statistical Package for Social Sciences (SPSS) version 26. Using independent t-test, continuous variables (Age and procedural time) were compared and displayed as mean (SD). Using Chi-square test, categorical variables (complications) were compared and displayed as frequencies and percentages. Statistical significance was obtained when the *p*-value was ≤0.05.

RESULTS

A total of 78 patients were included in the final analysis. In Group-A 17(43.6%) were female and 22(56.4%) were males and in Group-B 16(41.1%) were females and 23(58.9%) were males. Age and gender should normal distribution whereas procedural time (*p*<0.01) showed non-normal distribution. The Average age in Group-A was 53.16±10.15 versus 54.28±9.35 in Group-B (Table-I). Procedural time was significantly longer in Group-A as compare to Group-B (18.42±8.13 versus 12.93±4.72 min, *p*<0.01) (Table-II) and Complications including, Bleeding (>50 mL) was observed in 15.4% cases in Group-A versus 9.2% cases in Group-B, whereas Hypoxia was observed 13.5% in Group-A versus 6.5% of cases in Group-B. However esophageal injury was not found in any of the group (Table-III).

Table-I: Comparison of Demographic Variables between Groups (n=78)

Parameters	Study Groups		<i>p</i> -value
	Group A (n=39)	Group B (n=39)	
Age (years); Mean ±SD	53.16±10.15	54.28±9.35	0.512
Gender; n(%)			
Male	22(56.4%)	23(58.9%)	0.341
Female	17(43.6%)	16(41.1%)	

Table-II: Comparison of Procedural Time between Groups (n=78)

Parameters	Study Groups		p-value
	Group A (n=39)	Group B (n=39)	
Mean±SD Procedural time (min)	18.42±8.13	12.93±4.72	0.01

Table-III: Comparison of Complications between Groups (n=78)

Complications	Study Groups		p-value
	Group A (n=39)	Group B (n=39)	
Hypoxia	5(13.5%)	2(6.5%)	0.01
Bleeding	6(15.4%)	3(9.2%)	0.02

DISCUSSION

This study compared fiberoptic bronchoscope (FOB) versus landmark-guided percutaneous dilatational tracheostomy (PCDT) in critically ill patients. Despite the widespread adoption of both FOB-guided versus mini-surgical technique for PCDT, there remains a considerable debate and a lack of definitive consensus regarding the routine use of bronchoscopic guidance.⁹ The landmark technique required significantly less time, while complication rates were comparable between groups, consistent with previous studies by Tariparast *et al.*, and Johnson-Obaseki, reported shorter duration for bedside percutaneous techniques.^{10,11}

Similar findings were observed by Gupta *et al.*, according to them, Percutaneous dilatational tracheostomy was less likely than surgical approach to cause hemorrhagic (2.6 percent vs. 7 percent, $p=0.002$) and desaturation (2.3 percent vs. 6.6 percent, $p=0.001$) issues. There were more ventilator-free days (VFD) and a shorter procedure duration (average shortening of 9.2 minutes) in the PDT group.¹² In study of Iftikhar *et al.*, Surgical tracheostomy, bronchoscopic-guided dilatational tracheostomy (BDT), ultrasound-guided (UDT), and anatomic landmark-based dilatational tracheostomy (ALDT) were the categories for tracheostomy techniques that did not necessitate any direct bronchoscopic or ultrasonographic imaging (SGT). Significant differences in process times between SGT and ALDT were found by pairwise meta-analysis [mean difference: 9.96 min (SE 3.18). & [15.67 minutes (SE 3.85)] between SGT and BDT.¹³

Conversely, some trials, such as reported by Nikbakhsh *et al.*, reported advantages of FOB guidance, citing reduced posterior tracheal wall injury and better control over puncture site selection. Semi-surgical percutaneous dilatational tracheostomy

(SSPDT) and conventional CPDT were compared in this study. The SSPDT group's procedure time was 5.16 ± 1.72 minutes, whereas the CPDT group's was 6.42 ± 1.71 minutes ($p<0.001$). In the SSPDT group, the complication rate was 7(8.75%), but in the CPDT group, it was 16(20%) ($p=0.043$).¹⁴ In our study, however, FOB guidance was associated with longer procedure time and a higher frequency of transient desaturation, aligning with studies of Jarosz *et al.*, that showed increased hypoxia due to partial airway obstruction during bronchoscopy.¹⁵

As per the study of Raimondi *et al.*, bronchoscopy, while enhancing visualization, compromises ventilation during the procedure and demands more operator skill. The reliance on additional personnel and equipment limits its practicality in busy ICUs.¹⁶

Recent evaluations of USG-guided PDT(percutaneous dilatation tracheostomy), showed promising results, offered real-time guidance and fewer vascular complications, as showed from study by Shen G *et al.*, they included 90 patients with mechanical ventilation and oral intubation who received PDT with (n=45, FOB-PDT group) and without (n=45, PDT group) FOB. The rate of first-time success was significantly different between the two groups (64.4 percent vs. 93.3 percent, $p<0.05$); the PDT-FOB group had a higher rate of first-time success puncture with the puncture needle than the PDT group (93.3 percent vs. 75.6 percent, $p<0.05$). Compared to the PDT-FOB group, the PDT group's mean procedure duration was substantially longer (12.9 ± 1.1 vs. 9.8 ± 1.2 min, $p<0.05$).¹⁷ In study by Lin KT *et al.*, PDTs were performed successfully in 74 patients in surgical ICU, mean time taken to perform tracheostomy was found 8.7 ± 4.5 with overall complications rate of 12.16% was recorded and the common perioperative complication was bleeding that occurred in 5(6.7%) patients.¹⁸ Our findings suggest that, in appropriately selected patients, the landmark technique remains safe and efficient, particularly where advanced imaging or bronchoscopic support is unavailable.

In study by Topcu *et al.*, the mean length of hospitalisation for all patients following tracheostomy was 60.83 days, and the mean length of tracheostomy procedures was 11.07 minutes for all patients, according to a comparison between the landmark approach and ultrasound-guided PDT. When the groups' tracheostomy durations were examined

independently, it was found that the Landmark group's tracheostomy took an average of 12.64 minutes to perform, whereas the ultrasound-guided PDT group's average was 6.47 minutes. Compared to the landmark technique group, the ultrasound-guided group's tracheostomy time was significantly shorter ($p=0.000$).¹⁹ In contrast to LT, UGT improved first-pass success (OR: 4.287; 95 percent confidence level), according to a meta-analysis of three randomized controlled trials (RCTs) and one nonrandomized controlled study (NRS), totaling 474 patients.²⁰

CONCLUSION

Percutaneous dilatation tracheostomy (PCDT) insertion with a Landmark technique demonstrated superior performance in terms of procedural time compared to the fiberoptic bronchoscope technique. These findings suggest that landmark technique is preferable over fiberoptic bronchoscope guided PCDT insertion in emergency settings.

Conflict of Interest: None.

Funding Source: None.

Authors' Contribution

Following authors have made substantial contributions to the manuscript as under:

SK & AB: Data acquisition, data analysis, critical review, approval of the final version to be published.

FTS: Study design, data interpretation, drafting the manuscript, critical review, approval of the final version to be published.

Authors agree to be accountable for all aspects of the work in ensuring that questions related to the accuracy or integrity of any part of the work are appropriately investigated and resolved.

REFERENCES

- Ghatts C, Alsunaid S, Pickering EM, Holden VK. State of the art: percutaneous tracheostomy in the intensive care unit. *J Thorac Dis* 2021; 13(8): 5261-5270. <https://doi.org/10.21037/jtd-21-918>
- Mehta C, Mehta Y. Percutaneous tracheostomy. *Ann Card Anaesth* 2017; 20(Suppl 1): S19-25. https://doi.org/10.4103/aca.ACA_36_17
- Brass P, Hellmich M, Ladra A, Ladra J, Wrzosek A. Percutaneous techniques versus surgical techniques for tracheostomy. *Cochrane Database Syst Rev* 2016; (7): CD008045. <https://doi.org/10.1002/14651858.CD008045>
- Klotz R, Probst P, Deininger M, Klaiber U, Grummich K, Diener MK, et al. Percutaneous versus surgical strategy for tracheostomy: a systematic review and meta-analysis of perioperative and postoperative complications. *Langenbecks Arch Surg* 2018; 403(2): 137-149. <https://doi.org/10.1007/s00423-017-1636-5>
- Uluç K, Öngel EA, İlkaya NK, Devran Ö, Özçelik HK. Indication, complication, and prognosis of fiberoptic bronchoscopy guided percutaneous dilatation tracheostomy in respiratory intensive care unit: a retrospective study. *Eur Rev Med Pharmacol Sci* 2023; 27(24): 11245-53. https://doi.org/10.26355/eurev_202312_34190
- Kumar P, Kumar S, Hussain M, Singh R, Ahmed W, Anand R, et al. Comparison of percutaneous tracheostomy methods in ICU patients: conventional anatomical landmark method versus ultrasonography method—a randomized controlled trial. *Indian J Anaesth* 2022; 66(Suppl 4): S207-212. https://doi.org/10.4103/ija.ija_41_22
- Zhang X, Zheng Y, Wang Z, Huang Y, Wang J, Jia L, et al. Comparison between fiberoptic bronchoscope-guided and landmark-based percutaneous dilatational tracheostomy: a systematic review and meta-analysis. *J Intensive Care Med* 2023; 38(3): 271-281. <https://doi.org/10.1177/08850666221123235>
- Kang HT, Kim SY, Lee MK, Lee SW, Baek A, Park KN, et al. Comparison between real-time ultrasound-guided percutaneous tracheostomy and surgical tracheostomy in critically ill patients: a randomized controlled trial. *Crit Care Res Pract* 2022; 1388225. <https://doi.org/10.1155/2022/1388225>
- Kumar P, Gupta A, Singh PK, Pandey S, Agarwal S, Singh U. Fiberoptic bronchoscopy versus mini-surgical technique for percutaneous dilatational tracheostomy: a randomized controlled trial. *J Intensive Care Med* 2021; 36(8): 891-900. <https://doi.org/10.1177/0885066620928294>
- Tariparast PA, Brockmann A, Hartwig R, Benschmidt B, Klemm K, Bohr C, et al. Percutaneous dilatational tracheostomy with single-use bronchoscopes versus reusable bronchoscopes – a prospective randomized trial (TraSUB). *BMC Anesthesiol* 2022; 22: 90. <https://doi.org/10.1186/s12871-022-01618-4>
- Johnson-Obaseki S, Veljkovic A, Javidnia H. Complication rates of open surgical versus percutaneous tracheostomy in critically ill patients. *Laryngoscope* 2016; 126(11): 2459-2467. <https://doi.org/10.1002/lary.26019>
- Gupta S, Tomar DS, Dixit S, Zirpe K, Choudhry D, Govil D, et al. Dilatational percutaneous vs surgical tracheostomy in intensive care unit: a practice-pattern observational multicenter study (DISSECT). *Indian J Crit Care Med* 2020; 24(7): 514-521. <https://doi.org/10.5005/jp-journals-10071-23463>
- Iftikhar IH, Teng S, Schimmel M, Duran C, Sardi A, Islam S, et al. A network comparative meta-analysis of percutaneous dilatational tracheostomies using anatomic landmarks, bronchoscopic, and ultrasound guidance versus open surgical tracheostomy. *Lung* 2019; 197(3): 267-275. <https://doi.org/10.1007/s00408-019-00230-7>
- Nikbakhsh N, Amri F, Monadi M, Amri P, Bijani A. Semi-surgical percutaneous dilatational tracheostomy vs. conventional percutaneous dilatational tracheostomy: a prospective randomized trial. *Casp J Intern Med* 2021; 12(3): 249-256. <http://doi.org/10.22088/cjim.12.3.249>
- Aly NM, Labib HA, Mohamed WA, Elbatsh YA. Ultrasound-guided percutaneous tracheostomy versus conventional tracheostomy: technique and outcome. *Med J Cairo Univ* 2021; 89(2): 233-241. <https://doi.org/10.21608/mjcu.2021.194984>
- Raimondi N, Vial MR, Calleja J, Quintero A, Cortés A, Celis E, et al. Evidence-based guidelines for the use of tracheostomy in critically ill patients. *J Crit Care* 2017; 38(1): 304-318. <https://doi.org/10.1016/j.jcrc.2016.10.020>

Percutaneous Dilatation Tracheostomy Tube

17. Shen G, Yin H, Cao Y, Zhang M, Wu J, Jiang X, et al. Percutaneous dilatational tracheostomy versus fibre-optic bronchoscopy-guided percutaneous dilatational tracheostomy in critically ill patients: a randomized controlled trial. *Ir J Med Sci* 2019; 188(2): 675-681.
<https://doi.org/10.1007/s11845-018-1878>
 18. Lin KT, Kao YS, Chiu CW, Lin CH, Chou CC, Hsieh PY, et al. Comparative effectiveness of ultrasound-guided and anatomic landmark percutaneous dilatational tracheostomy: a systematic review and meta-analysis. *PLoS One* 2021; 16(10): e0258972.
<https://doi.org/10.1371/journal.pone.0258972>
 19. Topcu H, Ozçiftçi S, Şahiner Y. Comparative effectiveness of real-time ultrasound-guided tracheostomy and anatomic landmark percutaneous dilatational tracheostomy: a retrospective cohort study. *Eur Rev Med Pharmacol Sci* 2022; 26(21): 7910-7917.
 20. Latial T, Shree S, Mishra K, Mishra S, Mustajab MA, Gupta M, et al. Comparison of percutaneous single-stage dilatational tracheostomy and surgical tracheostomy in critically ill patients: a randomized controlled trial. *Int J Crit Illness Inj Sci* 2024; 14(1): 9-14.
https://doi.org/10.4103/ijciis.ijciis_53
-