

## ORIGINAL ARTICLES

### HISTOLOGICAL COMPARISON OF HUMAN THYMUS GLANDS BETWEEN GROUPS OF DIFFERENT AGES

Shafqat Ali, Liaqat Ali Minhas, Muhammad Arshad

Army Medical College Rawalpindi

#### ABSTRACT

**Objective:** To compare the thickness of the capsule and interlobular connective tissue, and number and diameter of Hassal's corpuscles in human thymus between two groups of young and old patients.

**Study Design:** Comparative study.

**Place and Duration of Study:** The study was carried out in the Anatomy Department at Army Medical College Rawalpindi from Sep 2007 to Oct 2007.

**Material and Methods:** Forty specimens of human thymus were separated into two groups: Group A included 20 specimens from patients between 1-25 years while Group B had same number of specimens of more than 40 years of age. These specimens were fixed in 10% formalin solution and then processed for paraffin embedding. Five micron thick sections were made. Haematoxylin and eosin stain, and PAS stain were used. The thickness of thymic capsule and interlobular connective tissue, number and diameter of Hassal's corpuscles in both groups were noted.

**Results:** Statistically significant differences were found in the thickness of capsule and interlobular connective tissue, number and size of Hassal's corpuscles in specimens of different age groups.

**Conclusion:** In old age, there is definite increase in the thicknesses of capsule and interlobular connective tissue with Hassal's corpuscles decreasing in number but increasing in diameter.

**Key words:** Human thymus, Aging, thymic capsule, Hassal's corpuscles, involutionary changes.

#### INTRODUCTION

In the immune system, T lymphocytes are central regulatory and effector cells. Thymus plays a critical role in the early development of immune system function, as T lymphocytes develop and mature here [1]. The gross abnormalities in immune function under normal conditions are not seen in thymectomized adults due to the presence of post-thymic peripheral T cells. As the peripheral pool of T cells get depleted, new T cells generating ability of thymus becomes especially and critically important [2]. Increased incidence of serious infections in old age has been related with decreased thymic function [3].

Thymus is almost fully developed at birth [4]. It has been found to undergo many

changes as the age advances [5]. These changes have been reported to start between 11-15 years [6]. There is reduction in the parenchyma of the gland and by middle age most of it has been replaced by fat although functional thymic tissue is found until 6th decade of life [7].

In an animal study on rats, it was reported that a progressive increase in amount of connective tissue and fat cells between thymic lobules was found with advancing age [8]. It was revealed in another animal study on guinea pig that first peripheral lymphocytes and then adipose tissue begin to accumulate within thymic perivascular space with advancing age [9]. As adipose tissue increases within perivascular space, there is a decrease in the volume of thymic epithelial space and hence less thymopoiesis [9].

The review of published medical literature reveals that most of the studies of thymic involution with age have been

---

**Correspondence:** Lt Col (R) Shafqat Ali, Anatomy Department, Army Medical College Rawalpindi  
Email: shafqat87@hotmail.com

Received: 13 March 2009; Accepted: 06 April 2009

performed on mice and other animals but literature concerning the changes in human thymus with advancing age is limited. Moreover not much emphasis has been given to the quantitative measurement of changes in certain parameters of human thymus with advancing age.

This study was planned to investigate the changes in histological features of human thymus like thickness of capsule and connective tissue between lobules, and number and size of Hassal's corpuscles in two different age groups.

### **MATERIAL AND METHODS**

Forty specimens of tissue sections of human thymus of different ages were obtained from AFIC Rawalpindi during open chest surgery. These specimens were separated in two groups with 20 specimens in each. Group A included specimens from patients between 1-25 years while Group B consisted of specimens from the patients beyond 40 years of age. As the study was not concerned with correlation of study variables with age progression rather it aimed to compare changes in these variables at different ages so it was not thought necessary to include ages 26-39. Tissue sections of specimens were placed in numbered bottles containing 10% formalin solution. These formalin fixed samples were embedded in paraffin wax. 5-micron thick sections were made on rotary microtome. These sections were then deparaffinized and stained using haematologin and easin (H&E) and periodic acid Schiff (PAS) stains. Micrometric measurement of parameters was done. The thickness of thymic capsule and interlobular connective tissue and diameter of Hassal's corpuscles were measured in three randomly selected different fields of each section under 40X objective. Similarly the number of Hassal's corpuscles was counted for each section. The arithmetic means of these measurements were calculated.

### **STATISTICAL ANALYSIS**

The data was analyzed using Computer software SPSS version 11.0. Descriptive

statistics were used to describe the data. Independent samples t-test was used to compare the study variables between two groups. P-value < 0.05 was considered as significant.

### **RESULTS**

On gross examination, in Group A the thymus was seen to be pale or grey in colour whilst that in Group-B was found as yellowish. The sections were surrounded by thin layer of irregular connective tissue (identified as capsule), from which septa went into the substance of the gland dividing it into various compartments, identified as thymic lobules. These connective tissue extensions were identified as interlobular septa. It was found that the separation between the lobules was not complete (Fig-1).

While there were no or few adipose cells visible in the sections taken from patients of Group A, the sections in Group B showed a lot of adipose tissue (Fig 1-2).

The mean thickness of the thymic capsule in Group-A cases was  $172.30 \pm 6.32$  micron and of those in Group-B was  $239.45 \pm 2.85$  micron and the difference in thickness of thymic capsule of Group-A and Group-B was statistically highly significant ( $P < 0.001$ -Table-1).

The mean thickness of the interlobular connective tissue of specimens in Group-A was  $28.9 \pm 4.29$  micron and of those from Group-B was  $55.15 \pm 3.33$  micron and the difference in thickness of interlobular connective tissue of Group-A and Group-B specimens was statistically highly significant ( $P < 0.001$ -Table-1).

The mean number of Hassal's corpuscles found in the medulla of the specimens in Group-A was  $1.58 \pm 0.04$  and of those in Group-B was  $0.77 \pm 0.13$  and the difference in number of Hassal's corpuscles between A and B group specimens was statistically highly significant ( $P < 0.001$ -Table-1).

The mean diameter of Hassal's corpuscles found in the medulla of thymic specimens in Group-A was  $103.53 \pm 5.73$

micron and of those from Group-B was 151.41 ± 6.67 micron. The difference in the diameter of Hassal’s corpuscles of A and B group specimens was statistically significant (P < 0.05 -Table-1).

The comparison was made in these histological parameters of male and female persons of Group A; it was observed that the difference between sections from both sexes in terms of these parameters was statistically insignificant (Table-2). Similar comparison was not possible in Group B as sufficient number of specimens from female patients were not available at that time.

colour in an animal study. They also observed that the aged thymus is difficult to differentiate from mediastinal fat during thoracic surgery.

The difference between thicknesses of capsule of two groups of patients was statistically significant and was found to be higher in old age group. Previously similar results have been given for animals [8 and 11).

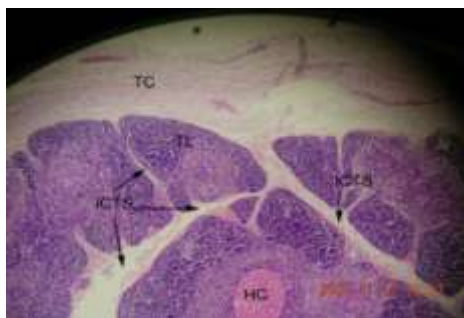The mean thickness of connective tissue septa between the thymic lobules showed statistically highly significant increase. It was

**Table- 1: Parameters in different groups**

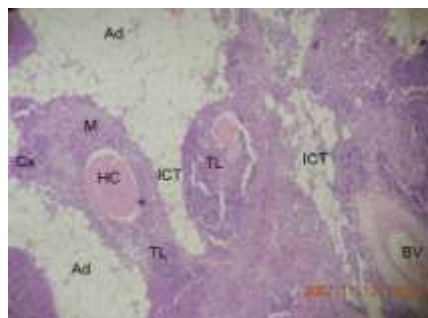
Parameter	Group A	Group B	P-value
Thickness of thymic capsule, (Mean ± SE)	172.30 ± 6.32	239.45 ± 2.85	< 0.001
Thickness of Interlobular connective tissue, (Mean ± SE)	28.90 ± 4.29	55.15 ± 3.33	< 0.001
Number of Hassal's corpuscles, (Mean ± SE)	1.58 ± 0.04	0.77 ± 0.13	< 0.001
Diameter of Hassal's corpuscles, (Mean ± SE)	103.53 ± 5.73	151.41 ± 6.67	< 0.05

**Table- 2: Parameters in group “A” male and female cases**

Parameter	Male	Female	P-value
Thickness of thymic capsule, (Mean ± SE)	168.00 ± 6.97	173.60 ± 6.67	> 0.05
Thickness of Interlobular connective tissue, (Mean ± SE)	27.30 ± 5.04	25.50 ± 2.72	> 0.05
Number of Hassal's corpuscles, (Mean ± SE)	1.66 ± 0.16	1.50 ± 0.21	> 0.05
Diameter of Hassal's corpuscles, (Mean ± SE)	106.00 ± 7.53	101.00 ± 5.64	> 0.05



**Fig-1: A photomicrograph from a section of human thymus Group-A (2 years). H & E x 40.**



**Fig-2: A photomicrograph of a section of human thymus Group-B (48 years). H & E x 40.**

Key for abbreviations used in figures:

TC: Thymic capsule, TL: Thymic lobule, ICTS: Interlobular connective tissue septum, HC: Hassal’s corpuscles, Cx: Cortex, M: Medulla, Ad: Adipose tissue, BV: Blood vessel.

**DISCUSSION**

On gross examination, the thymus glands in Group A were found to be pale or grey while in Group B, these were yellowish in colour. This change in colour is due to the infiltration of adipose tissue with advancing age as reported by Baron et al [10]. Hale et al. [3] also documented a similar change in

seen to be due to the gradual deposition of fat/adipose tissue between the lobules with advancing age. It is in accordance with an earlier study [11] on rat thymus where a similar increase in the content of interlobular connective and adipose tissue with advancing age was reported. It has also been supported in another animal study on rat thymus [8].

As all the glands were surrounded by a connective tissue layer forming the capsule of varying thickness, the connective tissue septa from this capsule were seen to protrude into the gland dividing it into lobules. It is consistent with an earlier study [12]. These lobules were incomplete and communicated with each other. The Group-B sections showed disappearance of interlobular septa as these were replaced by infiltration of adipose tissue. Smith and Gomez documented disappearance of septa, attrition of demarcation between cortex and medulla [13] while loss of septa with increased fatty infiltration in aging rats was also a main feature of another study [14].

In Group-B, the sections were altogether consisting of adipose tissue with only a few islands of thymic tissue in contrast to the Group A sections which showed less adipose cells. It is in accordance with an earlier radiological study [10] where a gradually increasing fatty atrophy of thymus after puberty was reported. This study however did not support its result histologically.

The difference between mean numbers of Hassal's corpuscles in two groups was found to be statistically highly significant, as it showed a decrease in Group B. This observation is consistent with Hassal [15] who reported an initial increase with a decrease in later part of life. Majeed et al [14] documents a decrease in number of Hassal's corpuscles in rat thymus with aging. Smith and Gomez [13] also supported this observation. Similarly the difference between mean diameter of Hassal's corpuscles in two groups was found to be statistically significant as it increased with advancing age. It is again in agreement with an earlier study [13]. Longstanding view about the role of Hassal's corpuscles has been of a graveyard for the effete lymphocytes [5]. Recently it has been shown that the epithelial cells within Hassal's corpuscles express thymic stromal lymphopoietin (TSLP), a chemical signal that directs a specialized group of dendritic cells to turn some of bad T cells escaping the thymic censorship process into good regulatory T cells [16].

## CONCLUSION

The present study meets its objective of comparing thickness of capsule and interlobular connective tissue, number and diameter of thymic corpuscles in groups of patients of different ages. In old age, there is definite increase in the thickness of capsule and interlobular connective tissue with Hassal's corpuscles decreasing in number but increasing in diameter. It is concluded that there is a significant difference in humans of different age in terms of these parameters. A project with more available resources and specimens is suggested to study incremental changes occurring with progressive age in both genders.

## REFERENCES

1. Picker, L., Siegleman, M. In: Paul, WE, editor. *Fundamental immunology*. New York: Raven Press. 1993; 145-97.
2. Mackall, CL., Fleisher, TA., Brown, MR., Andrich, MP., Chen, CC., Feuerstein, IM., Horowitz, ME., Magrath, IT., Shad, AT., Steinberg, SM., Wexler, LH., Gress, RE. Age, thymopoiesis, and CD4+ T-lymphocyte regeneration after intensive chemotherapy. *New Engl J Med*. 1995; 332: 143-9.
3. Hale, Laura P., Amy G. Clark, Jie Li., Paula, K. Greer and Virginia Byers Kraus.). Age related thymic atrophy in the guinea pig. *Developmental and comparative immunology*. 2001; 25: 509-18.
4. Steinmann, G. Changes in the human thymus during ageing. *Current Topics: In Pathology*. 1986; 75: 43-80.
5. Standerling, S., Ellis, H., Healy, J.C., Johnson, D. and Williams, A. *Gray's anatomy- The Anatomical Basis of Clinical Practice*. 39th ed. Churchill Livingstone, Elsevier New York. 2005; 980-984.
6. Kendall, M.D., Johnson, H. and Singh, J. The weight of the human thymus gland at necropsy. *J Anat*. 1980; 131: 485-99.
7. Haynes, B.F., Markert, M.L., Sempowski, G.D., Patel, D.D. and Hale, L.P. The role of thymus in immune reconstitution in aging, bone marrow transplantation, and HIV-I infection. *Ann. Rev. Immunol*. 2000; 18: 529-60.
8. Elcuman, E.A., and Akay, M.T. Age dependent immunolocalization of fibronectin and histological changes in the thymus of rats. *Veterinary research communications*. 1998; 22: 8: 525-32.
9. Flores, K.G., Li, J., Sempowski, G.D., Haynes, B.F. and Hale, L.P. Analysis of human thymic perivascular space during aging. *J Clin Invest*. 1999; 104: 1031-9.
10. Baron, R.L., Lee, J.K.T., Sagel, S.S. and Peterson, R.R. Computed tomography of the normal thymus. *Radiology*. 1982; 142: 121-5.
11. Solarovic-Plecas, B., Pesic, V., Radojevic, K. and Laposavic, G. Morphometrical characteristics of age-associated changes in the thymus of old male wistar rats. *Anat Histol Embryol*. 2006.

12. Bearman, R.M., Levine, G.D. and Bensch, K.D The ultra structure of normal human thymus- a study of 36 cases. *Anat Rec.* 1978; 190: 755.
  13. Smith, S.M. and Gomez-Ossa, L.J. A quantitative histologic comparison of the thymus in 100 healthy and diseased adults. *Am J Clin Pathol.* 1981; 76: 5: 657-65.
  14. Majeed, N., Fatani, J.A., Moustafa, F.A. and Mohajir, A.M. Reappraisal of age-related morphological changes in the rat thymus-morphometric study. *Funct Dev Morphol.* 1991; 1: 2: 57-60.
  15. Hassal, A.H. The microscopic anatomy of the human body, in health and disease. London. 1846; 9.
  16. Wing, K., Fehervari, Z. and Sakaguchi, S. Emerging possibilities in the development and function of regulatory T cells. *International Immunology.* 2006; 18: 7: 991-1000.
- .....