

## CHONDRITIS AND AURICULAR BURN

Samer Haddad, Lara Abu Ghazaleh, Awni Abulail

King Hussein Medical Center, Jordan

### ABSTRACT

**Objective:** Auricular burn is a common injury encountered in the burn patients. It has devastating complications including chondritis, hypertrophic scars and hyperpigmentation, the worse of which is chondritis inevitably leading to deformity. The study shows our experience in prevention, early detection and proper management of auricular burn and chondritis.

**Study Design:** A retrospective descriptive study.

**Place and Duration of Study:** This study was conducted at the Royal Rehabilitation Centre, King Hussain Medical Centre, Jordan from January 2000 to December 2005.

**Patients and Methods:** All the patients admitted to the burn unit at the Royal Rehabilitation Center at King Hussein Medical Center from January 2000 through December 2005 with burn involving the ear were included in the study. The ears were managed locally with topical antibiotics and light pressure dressing. Early detection of chondritis was undertaken and early management with surgical intervention and proper dressing was applied.

**Results:** A total of 62 patients (11.5%) out of 537 had ear burn, 71% were due to direct flame burn. Chondritis developed in 10.8% of patients with deep superficial and full thickness direct flame burned ears. Twelve and half percent of ears were lost, 25% had mild deformity, and 62.5% of ears developed moderate deformity. Hyperpigmentation occurred in 21.6% of ears and 9.5% developed hypertrophic scars.

**Conclusion:** Chondritis is a devastating complication after auricle burn. The incidence of chondritis can be decreased by proper care of the burned ear and avoidance of infection. Early detection and proper management of this condition can decrease the severity of deformity as sequelae of chondritis.

**Key words:** auricle, burn, chondritis, deformity.

### INTRODUCTION

The auricle is a relatively common injured organ in head and neck injuries. It has a very unique anatomical feature as the skin is directly attached to the perichondrium, which makes the cartilage vulnerable to thermal injuries [1]. The cosmetic shops and earring kiosks used piercing methods are some other factors that predispose to auricular chondritis. A large outbreak in 2003 of auricular chondritis associated with piercing caused serious consequence for infection. Auricular injury can lead to early complications most commonly chondritis, and late complications including deformity, hypertrophic scars, discoloration or complete loss of the ear [1-4]. Managing such injuries is challenging and crucial to avoid devastating complications in

field of cosmetic surgery. The location of the wound in the auricular subunit is predictive of the cosmetic result. Emergency physicians need to be aware of the severity of these types of infections, which often require surgical management and intravenous antibiotics covering *Pseudomonas*. Risk factors for infection included piercing or injury location and the use of a contaminated aftercare solution.

This is a retrospective study carried out on patients admitted with auricular thermal injury to the burn unit at the Royal Rehabilitation Center at King Hussein Medical center, Jordan. They were studied regarding age, causes of thermal injury and depth of burn, to determine the effect of proper management and prevention of infection on the outcome of auricular burn and complications specially chondritis.

This study conducted here in Jordan may help our colleagues to assess and rectify the

**Correspondence:** Dr. Samer Haddad, Dept of Plastic and Reconstructive Surgery, Royal Rehabilitation Centre, King Hussain Medical Centre, Jordan

Received: 16 Feb 2008; Accepted: 11 Sep 2008

devastating complications including chondritis, hypertrophic scars and hyperpigmentation, the worse of which is chondritis inevitably leading to deformity.

### PATIENTS AND METHODS

This is a retrospective study conducted during the five-year period from January 2000 through December 2005 reviewing all the patients admitted to the burn unit at the Royal Rehabilitation Center at King Hussein Medical Center, Jordan. All patients with auricular injury were included in the study. After proper resuscitation of the burned patients, the patients' ears were evaluated for the depth and distribution of the burn in the affected auricle. The hair around the ear was shaved, and the ears were washed with saline and dressed with topical antibiotics; silver sulphadiazine, twice daily. A crucial point was that the dressing was done with no pressure. In the presence of necrotic tissue careful debridement was done. This treatment continued until complete healing occurred. After discharge the patients were followed up in the burn clinic for minimum period of 12 months. The patients were observed closely for the most serious complication of auricular burn, which is chondritis. Recent onset of pain, redness, warmth and swelling suggested the presence of chondritis. The presence of tenderness upon movement of the auricle (springing sign) or the presence of collection indicated surgical intervention. Bivalve technique [1] was used where a long incision was made along the helical margin of the ear as it opens in a bivalve fashion to expose the underlying collection and cartilage (Fig. 1, 2).

The necrotic cartilage was excised and the ear was dressed with fine mesh gauze soaked in Povidone-iodine, an antibacterial solution, and saline to reduce the risk of progressive infection. A light dressing was applied over the ear without pressure, this was changed twice daily. The patients were given a course of third generation Cephalosporins with Lincomycin 3 times daily. The dressing was continued daily to allow the wound to heal with secondary

intention. The patients were followed for a period of at least 12 months for the outcome. None of the patients were lost during the follow up.

### RESULTS

During the period from January 2000 through December 2005, 537 patients were admitted to the burn unit of the Royal Rehabilitation Center at King Hussein Medical Center. 62 patients (11.5%) had burned ears with a total of 74 ears involved. 12 patients (19.4%) had both ears involved. The average age for patients of auricular burn was 37.5 years (range 6 months to 62 years) with a standard deviation of 17.6. The average Total Body Surface Area % (TBSA%) burned was 32.8% (range 4%-48%) with standard deviation of 8.8 (Table-1). 44 patients (71%) had direct flame burn injuries, 16 patients (25.8%) had scald burns, 2 patients (3.2%) had high voltage electrical and flash burn (Fig. 3)

The anterior surface of the ear was involved in 60 ears (81%), while both the anterior and posterior surface was involved in 14 ears (19%). The degree of burn was as follows: 20 ears (27%) were of superficial partial thickness burn, 46 ears (62.2%) were of deep partial thickness and 8 ears (10.8%) were of full thickness burn (Fig. 4)

Chondritis developed in 8 ears (10.8%). 6 ears (75%) developed the chondritis during admission in the first 2 weeks and 2 ears (25%) presented 3 weeks post burn after discharged. All the affected ears were from the direct flame burn group of patients. Five ears (62.5%) were from full thickness burn group and three ears (37.5%) with deep partial thickness burn. 7 ears (87.5%) had both surfaces of the ear burned and 1 ear (12.5%) with the anterior surface only burned (Table-2)

The average time of healing was 7 weeks (range 5-8 weeks). The incidence of deformity post chondritis was as follows; severe deformity with complete loss of external ear in one ear (12.5%), moderately deformed with more than 50% of the auricle involved where the upper half of the auricle, antihelix and its

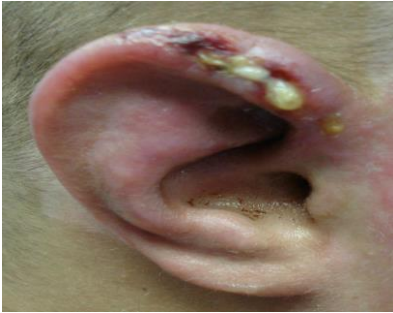

Fig.1: Post burn chondritis needing for surgical intervention

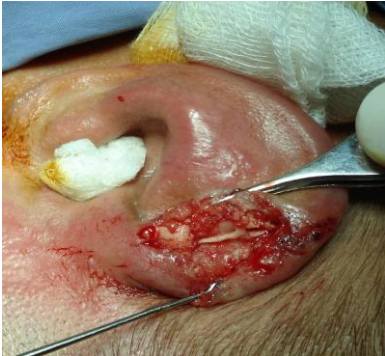

Fig. 2: Bivalve technique using long incision

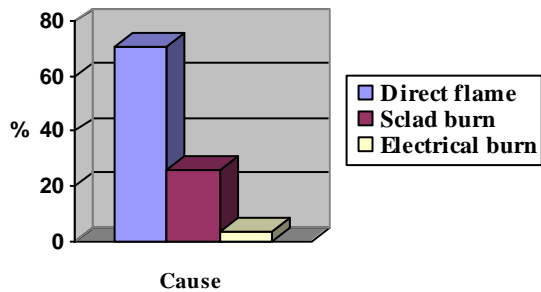


Fig. 3: Percentage and causes of auricular burn

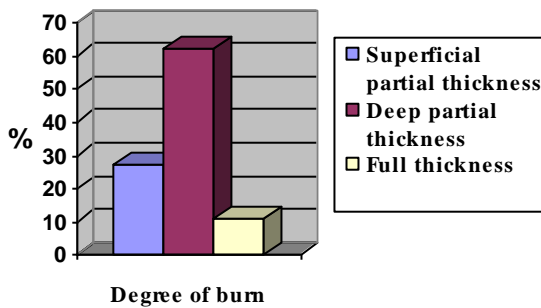


Fig. 4: Depth of burn in the affected ears

posterior crura are missing in five ears (62.5%) and mild deformity with less than 50% of the auricle involved with loss of helix and upper auricle in two ears (25%) (Table-3). From the total number of ears involved in thermal injury there were 16 ears (21.6%) with

Table-1: Demographic data of the patients

Total number of patients admitted	537 patients
Total number of patients with burned ears	62 (11.5%)
Total number of burned ears	74 ears
Total number of both ears involved	12 (19.4%)
Mean age of patients	37.5 years
Mean TBSA%	32.8%

Table-2: Demographic data of chondritis

Number of cases with chondritis	8
Deep partial thickness burn	3
Full thickness burn	5
Chondritis in ears of both surfaces involved	7
Chondritis in ears of anterior surface involvement	1

Table-3: Patients and degree of ear deformity post chondritis

Complication	No. of patients
Mild deformity	2
Moderate deformity	5
Complete loss (severe deformity)	1

hyperpigmentation, and 7 ears (9.5%) with hypertrophic scars.

## DISCUSSION

Thermal injury to the ears is a frequent finding in burned patients. The ear has a peculiar anatomy where the skin is attached to the perichondrium without any subcutaneous tissue and so has little protection of the underlying cartilage. The blood supply to the auricle is from central vessels [4] that can be compromised in a burned ear secondary to edema and thrombosis leading to chondritis and auricle deformity [1, 2, 5, 6]. The ear also has a unique position on the face with an angle that makes the anterior surface most vulnerable to the burn; this is the reason for the higher incidence of anterior surface burn in our study and in other studies as well (1, 5-8).

In our study the most common cause of auricle burn was direct flame burn (71%) followed by scald burn (25.8%) and electrical burn (3.2%), this distribution is consistent with the distribution of all burned patients

admitted to the burn unit in other studies [1, 7, 8].

After proper resuscitation of the burned patients admitted to the burn unit special care was taken for the burned ears. The periauricular hair was cut, the ear was washed with saline and dressed lightly with silver sulphadiazine, twice daily [1]. Avoidance of pressure was a key point in avoiding chondritis and infection and so deformity [1-3, 5-9]. Prevention of infection is the major preventive factor to chondritis [1, 3-8, 10]. Intravenous antibiotics were not used initially unless the general condition of the patient indicated their use.

27% of the patients had superficial partial thickness burn, 62.2% had deep partial thickness burn and 10.8% had full thickness burn. Patients were followed up carefully for increased pain, swelling, warmth or redness of the auricle, which indicated early perichondritis. The springing sign (pain with auricle movement) was an important sign in diagnosis [1, 2, 5, 7, 8].

The average development of chondritis is between 5%-25% in different studies [1-3, 5-9], in our study eight ears (10.8%) developed chondritis. Although 6 ears (75%) presented during admission, 2 ears (25%) presented after being discharge from the hospital. The average time of onset was around 2-3 weeks post burn which is the time taken for the cartilage to be necrotic. All were treated surgically using the bivalve technique by a long incision over the helix to drain the pus and excise the necrotic cartilage [1, 7, 8]. Multiple debridements were done occasionally when needed. The dressing was done with saline and Povidone-iodine with light dressing avoiding pressure. The patients were put on a course of antibiotics. The wounds were left to heal by secondary intention. The healing time ranged from 5-8 weeks depending on the degree of infection and debridement. The cause of ear burn in all the patients with chondritis was direct flame burn. 87.5% of the ears with chondritis had both anterior and posterior surfaces burned, and 62.5% of ears were from the full thickness

burn. We found that the deeper the burn the higher the incidence of chondritis, this is consistent with the findings in other studies [1, 6-8]. Although the development of chondritis is inevitable in some cases, an early detection of this serious condition and proper early management can decrease the severity of the subsequent deformity and total loss [4].

25% of patients with chondritis developed mild auricular deformity that involved destruction of less than 50% of the helix, 62.5% of ears had moderate deformity that involves destruction of more than half the auricle, and 12.5% of ears were completely lost. These results are similar to other studies [1, 3, 7, 8].

Other complications regarding thermal injury to the ears were hyperpigmentation, which occurred in 21.6% of burned ears and hypertrophic scars in 9.5% of ears.

## CONCLUSION

Chondritis and ear deformity is a devastating complication of auricle burn. Although chondritis is an irreversible complication, proper management of the burned ear and early detection of chondritis can decrease the severity of the subsequent deformity. The incidence of chondritis can be decreased by early local care, topical antibiotic and avoidance of pressure of the burned ear. The development of chondritis must be managed properly with debridement of necrotic cartilage. The best way to avoid deformity is by prevention of chondritis because the affected ear can never return back to normal shape.

## REFERENCES

1. Kamal A, Kamel AH, El Oteify M. Early Management of the Burned Auricle. *Ann Burn and Fire disaster*. 2004; 17: 4: 197-200.
2. Caputo G, Monese C, Governa M, Barisoni D. Conservative Treatment in Auricle Burn. *Ann Burn and Fire Disaster* 2005; 18: 4: 217-8.
3. Purdue GF, Hunt JL. Chondritis of the burned ear: a preventable complication. *Am J Surg* 1986; 152: 3: 257-9.
4. Nigm RC. The burned ear II: A prospective clinical study of 100 patients with 150 ear burns. *Ann Acad Med Singapore* 1992; 21: 605-11.

## Chondritis

Pak Armed Forces Med J 2009; 59(3):290-4

5. Mills DC, Roberts LW, Mason AD. Suppurative chondritis: its incidence, prevention and treatment in burn patients. *Plast Reconstr Surg.* 1988; 82: 267.
  6. Dowling JA, Foly FD, Moncrief JA. Chondritis in the burned ear. *Plast Reconstr Surg.* 1968; 42: 115-22. Quoted from *Clinics in Plastic Surgery.* 1992; 19: 3.
  7. Skedros DG, Goldfarb IW, Slater H, Rocco J. Chondritis of the burned ear. *Ear Nose Throat J.* 1992; 71: 359-62.
  8. Bentrem DJ, Bill TJ, Himel HN. Chondritis of the ear: a late sequela of deep partial-thickness burns of the face. *J Emerg Med.* 1996; 14: 469-71.
  9. BG. Management of the acutely burned ear. *Burns.* 2003; 29: 7: 726-32.
  10. Engrav LH, Richey KJ, Walkinshaw MD et al. Chondritis of the burned ear: a preventable complication. *Ann Plast Surg* 1989; 23: 1.
- .....