

## Diagnostic Accuracy of Magnetic Resonance Cholangio-Pancreatography (MRCP) in Evaluating Obstructive Jaundice, Keeping Endoscopic Retrograde Cholangio-Pancreatography(ERCP) as Gold Standard

Irum Qaisar, Faran Nasrullah\*, Intisar Ul Haq\*\*, Rabia Younas\*\*\*, Yasar Shakeel, Muhammad Omer Aamir\*\*\*\*

Department of Radiology, Armed Forces Institute of Radiology and Imaging/National University of Medical Sciences (NUMS) Rawalpindi Pakistan, \*Department of Radiology, Combined Military Hospital, Hyderabad/National University of Medical Sciences (NUMS)Pakistan, \*\*Department of Surgery, Armed Forces Institute of Cardiology/National Institute of Heart Diseases/National University of Medical Sciences (NUMS) Rawalpindi Pakistan, \*\*\*Department of Radiology, Fazaia Ruth Pfao Medical College (FRPMC), Karachi Pakistan, \*\*\*\*Department of Radiology, Combined Military Hospital/National University of Medical Sciences (NUMS) Rawalpindi Pakistan

### ABSTRACT

**Objective:** To determine the diagnostic accuracy of Magnetic Resonance Cholangiopancreatography in evaluating obstructive Jaundice, taking Endoscopic Retrograde Cholangiopancreatography as the gold standard.

**Study Design:** Cross-sectional study.

**Place and Duration of Study:** Armed Forces Institute of Radiology and Imaging in collaboration with the Gastroenterology Department of Military Hospital, Rawalpindi Pakistan, from Jun to Dec 2019.

**Methodology:** Ninety patients with a history of obstructive Jaundice referred to the Armed Forces Institute of Radiology and Imaging for Magnetic Resonance Cholangiopancreatography were included in the study. Magnetic Resonance Cholangiopancreatography was followed by Endoscopic Retrograde Cholangiopancreatography within 48 hours. Magnetic Resonance Cholangiopancreatography results were compared with Endoscopic Retrograde Cholangiopancreatography and diagnostic accuracy was calculated.

**Results:** The mean age was 57.58±14.65 years. The study constituted 40 male (44.4%) and 50 female (55.6%) patients. The sensitivity, specificity, PPV, NPV and diagnostic accuracy of Magnetic Resonance Cholangiopancreatography, keeping Endoscopic Retrograde Cholangiopancreatography as the gold standard, were calculated as 91.04%, 89.04%, 95.31%, 76.90% and 90.0%, respectively. The positive likelihood ratio was 7, while the negative likelihood ratio was 0.10.

**Conclusion:** Magnetic Resonance Cholangiopancreatography is a non-invasive and safe investigation with excellent diagnostic accuracy in evaluating obstructive Jaundice. Thus, Magnetic Resonance Cholangiopancreatography may be an alternative to Endoscopic Retrograde Cholangiopancreatography, especially in cases without intervention or in pregnant females, as it is free from ionizing radiation.

**Keywords:** Diagnostic accuracy, Endoscopic retrograde cholangio-pancreatography, Magnetic resonance cholangio-pancreatography, Obstructive jaundice.

**How to Cite This Article:** Qaisar I, Nasrullah F, Haq IU, Younas R, Shakeel Y, Aamir MO. Diagnostic Accuracy of Magnetic Resonance Cholangio-Pancreatography (MRCP) in Evaluating Obstructive Jaundice, Keeping Endoscopic Retrograde Cholangio-Pancreatography(ERCP) as Gold Standard. Pak Armed Forces Med J 2023; 73(4): 1169-1172. DOI: <https://doi.org/10.51253/pafmj.v73i4.8741>

This is an Open Access article distributed under the terms of the Creative Commons Attribution License (<https://creativecommons.org/licenses/by-nc/4.0/>), which permits unrestricted use, distribution, and reproduction in any medium, provided the original work is properly cited.

### INTRODUCTION

Obstructive Jaundice is a type of Jaundice caused by an obstruction in the bile duct, which causes more bile and its byproducts, such as bilirubin, to enter the bloodstream, which may result in complications like ascending cholangitis, malabsorption, and hepatorenal syndrome.<sup>1,2</sup> Obstructive Jaundice most commonly presents as yellow discolouration of skin or sclera, loss of appetite and pain in the abdomen.<sup>3</sup>

Although ultrasonography is considered the ideal initial modality in investigating cholestasis, Magnetic Resonance Cholangiopancreatography (MRCP) and Endoscopic Retrograde Cholangiopancreatography (ERCP)

hold enhanced sensitivity for diagnosing the level, aetiology, and extent of biliary obstruction.<sup>4</sup> ERCP is considered the first-line diagnostic and therapeutic procedure in patients with obstructive Jaundice due to suspected biliary stricture as it not only ascertains the exact size and length of the stricture but also facilitates obtaining tissue samples for further histopathological diagnosis.<sup>5,6</sup> However, ERCP is an invasive procedure that may lead to complications like haemorrhage, infection and perforation.<sup>7</sup> MRCP is a relatively newer radiological investigation that non-invasively produces high-resolution images of the biliary system. It is free from ionizing radiation, making it suitable even for children or pregnant females.<sup>8,9</sup> It has emerged as a reliable, non-invasive investigation in diagnosing choledocholithiasis.<sup>10</sup>

**Correspondence:** Dr Faran Nasrullah, Department of Radiology, Combined Military Hospital, Hyderabad Pakistan

Received: 18 May 2022; revision received: 10 Apr 2023; accepted: 11 Apr 2023

This study aims to establish MRCP as a reliable and accurate diagnostic imaging modality in diagnosing obstructive Jaundice. Although few international studies have been conducted, local studies on this topic have been few. Our study can be employed to determine these parameters in our local population and can also be used to validate our local studies on this topic. Thus, it may prove that MRCP is a non-invasive alternative to ERCP, especially when no therapeutic intervention must be performed. This would result in reduced complications and a decline in the burden on gastroenterologists for performing ERCP, which would then only be done in cases requiring therapeutic management.

### **METHODOLOGY:**

The study was carried out at the Armed Forces Institute of Radiology and Imaging (AFIRI) in collaboration with the Gastroenterology Department of Military Hospital, Rawalpindi Pakistan, from June 2019 to December 2019 after approval from Institutional Ethical Committee (Certificate No. 0055). The sample size was calculated using the sensitivity of MRCP 100%, specificity being 95.8%, the prevalence of obstructive Jaundice 17.1%.<sup>11</sup> Non-probability, consecutive sampling was done.

**Inclusion Criteria:** Patients of either gender, aged from 15-90 years, presenting in the Outpatient Department, with jaundice (yellowish discolouration of skin and sclera) and deranged liver enzymes (Alkaline phosphatase more than 289 u/L) were included in the study.

**Exclusion Criteria:** Patients who had already undergone ERCP, had hypersensitivity to drugs employed in ERCP, were claustrophobic patients, patients having implanted MRI incompatible devices and patients having deranged coagulation profile were excluded from the study were excluded from the study.

The aim of the study was explained to each patient and informed written consent was taken. The complete past medical history of the patients was documented with emphasis on drug history, claustrophobia or any prior episode of Jaundice. Laboratory tests like complete blood counts, platelet counts, liver and renal function tests and coagulation profiles were recorded.

All the patients underwent MRCP on a 1.5T GE MRI machine. Four-hour fasting was essential to decrease the number of gastroduodenal secretions, weaken bowel peristalsis and prevent gall bladder contraction, thus improving the image quality. T1-

weighted and heavily T2-weighted sequences like STIR and FRFSE were carried out in axial and coronal planes. No intravenous or oral contrast agent was administered. A senior consultant Radiologist reported the MRCP of each patient, and the findings were documented. MRCP was declared positive if the intrahepatic biliary channels, hepatic ducts or common bile duct exhibited abnormal dilatation, narrowing or associated mass. The normal calibre of CBD was taken as up to 7 mm up to 40 years of age, with an increase of 1 mm every decade after that. MRCP was considered negative in the absence of such findings

Subsequently, a classified Gastroenterologist subjected each patient to an ERCP, which was done within 48 hours of performing the MRCP. An endoscope was inserted into the descending duodenum through the mouth, and the ampulla of Vater was cannulated, following which contrast was administered to visualize the biliary system. The findings of the ERCP examination were documented.

Statistical Package for the Social Sciences (SPSS) version 24:00 and Microsoft Excel were used for data analysis. Mean and standard deviation were computed for continuous variables, while frequency and percentages were determined for categorical variables. All the relevant statistical parameters like sensitivity, specificity, positive predictive value, negative predictive values and diagnostic accuracy of MRCP for diagnosis of obstructive Jaundice, taking ERCP as the gold standard, were calculated using a 2x2 contingency table.

### **RESULTS**

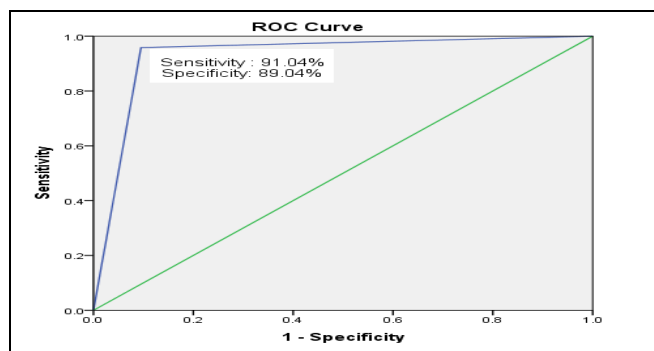
A total of 90 patients were included with a mean age of  $57.58 \pm 14.65$  years. Female patients were more, i.e. 50(55.6%), whereas male patients were 40(44.4%). The most common presenting symptom in our study was Jaundice (93.3%), followed by anorexia (78.9%) and vomiting (54.4%). 39(63.9%) patients displayed benign causes, the most common being calculus, in 28(71.8%) benign cases. As many as 22(36.1%) patients exhibited malignant aetiology, the commonest being carcinoma of the gall bladder, comprising 12(54.5%) of the malignant cases. There were 61 patients (75.3%) who were positive for obstructive Jaundice both on MRCP and ERCP (true positive), while 20 patients (22.2%) were negative on both MRCP and ERCP (true negative). On the other hand, three patients (3.33%) were positive on MRCP but negative on ERCP (false positive), while six patients (6.67%) were positive on ERCP but negative on MRCP (false negative), as shown in Table.

**Table: Comparison of Endoscopic Retrograde Cholangio-Pancreatography(ERCP) and Magnetic Resonance Cholangio-Pancreatography (MRCP) findings**

		ERCP Findings		Total
		Present	Not Present	
MRCP Findings	Present	61(67.8%) True Positive	3(3.33%) False Positive	64
	Not Present	6(6.67%) False Negative	20(22.2%) True Negative	26
Total		67	23	90

Sensitivity =  $61 / 61+6 \times 100 = 91.04\%$ , Specificity =  $20/20+3 \times 100=86.95\%$   
 PPV =  $61 / 61+3 \times 100 = 95.31\%$ , NPV =  $20 / 20+6 \times 100 = 76.9\%$ ,  
 Diagnostic Accuracy =  $61+20 / 61+3+6+20 \times 100 = 90.0\%$ , Positive likelihood ratio =  $0.91/0.13 = 6.98$ , Negative likelihood ratio =  $0.089/0.87 = 0.10$

Forty-one patients were diagnosed benign by both MRCP and ERCP, showing diagnostic accuracy of 93.62%. Benign causes included cholelithiasis, choledocholithiasis, post-surgical stricture and choledochal cyst. On the other hand, 35 patients were diagnosed as malignant by both MRCP and ERCP findings, with a diagnostic accuracy of 86.05%. Malignant causes included hepatic mass lesions (primary and secondary), cholangiocarcinoma, klatskin tumour and pancreatic adenocarcinomas (Figure).



**Figure-1: ROC curve showing Magnetic Resonance Cholangio-pancreatography (MRCP) with Endoscopic Retrograde Cholangio-Pancreatography (ERCP) as Gold Standard**

## DISCUSSION

Obstructive Jaundice may result from congenital (choledochal cyst), inflammatory (post-inflammatory ampullary stricture), obstructive (choledocholithiasis), traumatic or neoplastic (periampullary carcinoma) causes.<sup>12,13</sup> It is a frequently encountered disease. However, identifying the exact aetiology, establishing the level of obstruction and characterization as benign or malignant persists as a challenging ordeal.<sup>14</sup> Early, accurate establishment of diagnosis and timely commencement of treatment is imperative to prevent complications, which may range up to multiple organ

dysfunction syndrome.<sup>15,16</sup> Ultrasonography is advocated as the preliminary investigation for obstructive Jaundice, which guides the selection of patients who further need to undergo a more sophisticated investigation such as MRCP or an invasive procedure such as ERCP.<sup>17,18</sup>

In our study, the most prevalent symptom in our study was Jaundice (93.3%), followed by anorexia (78.9%) and vomiting (54.4%). Similar results have also been reported in a study regarding the patients of obstructive jaundice cases in India, showing more than 50% of patients were in the age group of 55-75 years, with the most frequent symptoms being Jaundice (91.67%), anorexia (77.78%) followed by abdominal discomfort (75%).<sup>19</sup>

In our study, the sensitivity, specificity, PPV, NPV and diagnostic accuracy of MRCP in obstructive Jaundice were 91.04%, 89.95%, 95.31%, 76.90% and 90.0%, keeping ERCP as the gold standard. A local study performed to detect the accuracy of MRCP for the detection of hepato-pancreatico-biliary abnormalities concluded that MRCP displayed excellent diagnostic accuracy for the diagnosis of biliary pathologies and preventing needless ERCPs with sensitivity, specificity, positive and negative predictive values of 87%, 80%, 83.3% and 84.2% respectively.<sup>20</sup>

## LIMITATIONS OF STUDY

The main limitation of the study was that some of the patients were unable to maintain the necessary breath hold, thus reducing the quality of the 3D sequence of MRCP. Despite being excellent at demonstrating the biliary tree, MRCP examination has a limited role in illustrating the pathologies of the adjacent organs.

## CONCLUSION

MRCP is a non-invasive and safe investigation with excellent diagnostic accuracy in evaluating obstructive Jaundice. Thus, MRCP may be an alternative to ERCP, especially in cases without intervention or in pregnant females, as it is free from ionizing radiation.

**Conflict of Interest:** None.

## Author's Contribution

Following authors have made substantial contributions to the manuscript as under:

IQ: & FN: Data acquisition, data analysis, drafting the manuscript, approval of the final version to be published.

IUH: & RY: Study design, drafting the manuscript, data interpretation, critical review, approval of the final version to be published.

YS: & MOA: Concept, data acquisition, drafting the manuscript, approval of the final version to be published.

## Magnetic Resonance Cholangio-Pancreatography (MRCP)

Authors agree to be accountable for all aspects of the work in ensuring that questions related to the accuracy or integrity of any part of the work are appropriately investigated and resolved.

### REFERENCES

1. Mesihovic R, Mehmedovic A. Better non-invasive endoscopic procedure: endoscopic ultrasound or magnetic resonance cholangiopancreatography? *Med Glas (Zenica)* 2019; 16(1): 40-44. <https://doi.org/10.17392/955-19>.
2. Chen HL, Wu SH, Hsu SH, Liou BY, Chen HL, Chang MH, et al. Jaundice revisited: recent advances in the diagnosis and treatment of inherited cholestatic liver diseases. *J Biomed Sci* 2018; 25(1): 75. <https://doi.org/10.1186/s12929-018-0475-8>.
3. Fargo MV, Grogan SP, Saguil A. Evaluation of Jaundice in Adults. *Am Fam Physician* 2017 ; 95(3): 164-168.
4. Mathew RP, Moorkath A, Basti RS, Suresh HB. Value and accuracy of multidetector computed tomography in obstructive jaundice. *Pol J Radiol* 2016; 2(1): 303-309. <https://doi.org/10.12659/PJR.896680>.
5. Gupta A, Singh A, Goel S, Tank R. Profile and pattern of obstructive jaundice cases from tertiary care teaching hospital of Uttar Pradesh. *Int Surg J* 2017; 4(2): 743-746
6. Halim A, Ahmad I, Iqbal J, Khan Z. The presentation and causes of obstructive jaundice in patients presenting to a tertiary care hospital. *J Med Sci* 2011; 19: 66-69.
7. Bhanbhro RJ, Maheshwari T, Jarwar M. Etiological pattern and early outcome of patients presenting with obstructive jaundice at Isra University Hospital, Hyderabad, Pakistan. *Rawal Med J* 2018; 43(1): 68-71.
8. Salim A, Jabbar S, Amen F. Demographic distribution and staging at presentation of patients presenting with obstructive jaundice of malignant origin at tertiary care level in Pakistan. *Proceedings Sheikh Zaid Post Grad Med Inst* 2018; 32(2): 41-48.
9. Farrukh SZ, Siddiqui AR, Haqqi SA, Muhammad AJ, Dheddi AS, Khalid SK, et al. Comparison of ultrasound evaluation of patients of obstructive jaundice with endoscopic retrograde cholangio-pancreatography findings. *J Ayub Med Coll Abbott* 2016; 28(4): 650-652.
10. Alsaigh S, Aldhubayb MA, Alobaid AS, Alhajjaj AH, Alharbi BA, Alsudais DM, et al. Diagnostic reliability of ultrasound compared to magnetic resonance cholangiopancreatography and endoscopic retrograde cholangiopancreatography in the detection of obstructive jaundice: a retrospective medical records review. *Cureus* 2020; 12(10): e10987.
11. Lee YN, Moon JH, Choi HJ, Kim HK, Choi SY, Choi MH, et al. Diagnostic approach using ERCP-guided transpapillary forceps biopsy or EUS-guided fine-needle aspiration biopsy according to the nature of stricture segment for patients with suspected malignant biliary stricture. *Cancer Med*. 2017; 6(3): 582-590. <https://doi.org/10.1002/cam4.1034>.
12. Lee SL, Kim HK, Choi HH, Jeon BS, Kim TH, Choi JM, et al. Diagnostic value of magnetic resonance cholangiopancreatography to detect bile duct stones in acute biliary pancreatitis. *Pancreatology* 2018; 18(1): 22-28. <https://doi.org/10.1016/j.pan.2017.12.004>
13. Singh A, Mann HS, Thukral CL, Singh NR. Diagnostic Accuracy of MRCP as Compared to Ultrasound/CT in patients with obstructive jaundice. *J Clin Diagn Res*. 2014; 8(3): 103-107.
14. Petrescu I, Bratu AM, Petrescu S, Popa BV, Cristian D, Burcos T, et al. CT vs. MRCP in choledocholithiasis jaundice. *J Med Life* 2015; 8(2): 226-231.
15. Gupta P, Gupta J, Kumar MP. Imaging in obstructive jaundice: what a radiologist needs to know before doing a percutaneous transhepatic biliary drainage. *J Clin Interv Radiol* 2020; 4(01): 31-37.
16. Alsaigh S, Aldhubayb MA, Alobaid AS, Alhajjaj AH, Alharbi BA, Alsudais DM, et al. Diagnostic reliability of ultrasound compared to magnetic resonance cholangiopancreatography and endoscopic retrograde cholangiopancreatography in the detection of obstructive jaundice: a retrospective medical records review. *Cureus* 2020; 12(10): e10987. <https://doi.org/10.7759/cureus.10987>.
17. Pavlidis ET, Pavlidis TE. Pathophysiological consequences of obstructive jaundice and perioperative management. *Hepato-biliary Pancreat Dis Int* 2018; 17(1): 17-21. <https://doi.org/10.1016/j.hbpd.2018.01.008>.
18. Farrukh SZ, Siddiqui AR, Haqqi SA, Muhammad AJ, Dheddi AS, Khalid SK. Comparison of Ultrasound Evaluation Of Patients Of Obstructive Jaundice With Endoscopic Retrograde Cholangio-Pancreatography Findings. *J Ayub Med Coll Abbottabad* 2016;28(4):650-652.
19. Gupta A, Singh A, Goel S, Tank R. Profile and pattern of obstructive jaundice cases from a tertiary care teaching hospital of Uttar Pradesh. *Int Surg J* 2017; 4(2): 743-746. <https://doi.org/10.18203/2349-2902.isj20170225>
20. Gondal M, Ch SM, Ahmad I, Hussain T, Awan S, Fatima K, et al. Accuracy of MRCP in Comparison with ERCP for Diagnosing Hepato-Pancreatico-Biliary Pathologies. *J Rawalpindi Med Coll* 2018; 22(2): 88-91.